

The Treatment of Gynecomastia Without Sharp Excision

Hilton Becker, M.D.

Reprinted from *Annals of Plastic Surgery*, Volume 24, Number 4, April, 1990. Published by Little, Brown and Company, Boston, Massachusetts. Copyright © 1990. All rights reserved. No part of this reprint may be reproduced in any form or by any electronic or mechanical means, including information storage and retrieval systems, without the publisher's written permission.

The Treatment of Gynecomastia Without Sharp Excision


Hilton Becker, M.D.

A new suction cannula is described that is able to dissect and aspirate breast tissue. The cannula has proven effective in treating gynecomastia without surgical resection of breast tissue.

Becker H: The treatment of gynecomastia without sharp excision. *Ann Plast Surg* 24:380, 1990

Address offprint requests to Dr. Becker, 2617 N. Flagler Dr., Ste. 304, West Palm Beach, FL 33407.

380 Copyright 1990 by Little, Brown and Company



Suction lipectomy has become a common adjunct in the treatment of gynecomastia. Undesired sequelae and the frequency of complications are reduced when suctioning is used compared with traditional excision [1]. In most cases, however, suctioning is used only to resect fatty tissue. Local excision is then performed to remove the residual core of breast tissue [3]. It has recently been shown that by using a thin, pointed cannula, small amounts of breast tissue can be aspirated through the cannula [2].

A new cannula has recently been used that facilitates breast tissue resection (Fig 1). The cannula has a projecting "basket" around the opening. This unique design actually dissects and breaks up the breast tissue, which is then aspirated through the cannula.

Four cases of gynecomastia have been treated over the last year using suction alone [4] no surgical resection of breast tissue has been necessary. All patients have been highly satisfied with their results (Figs 2, 3).

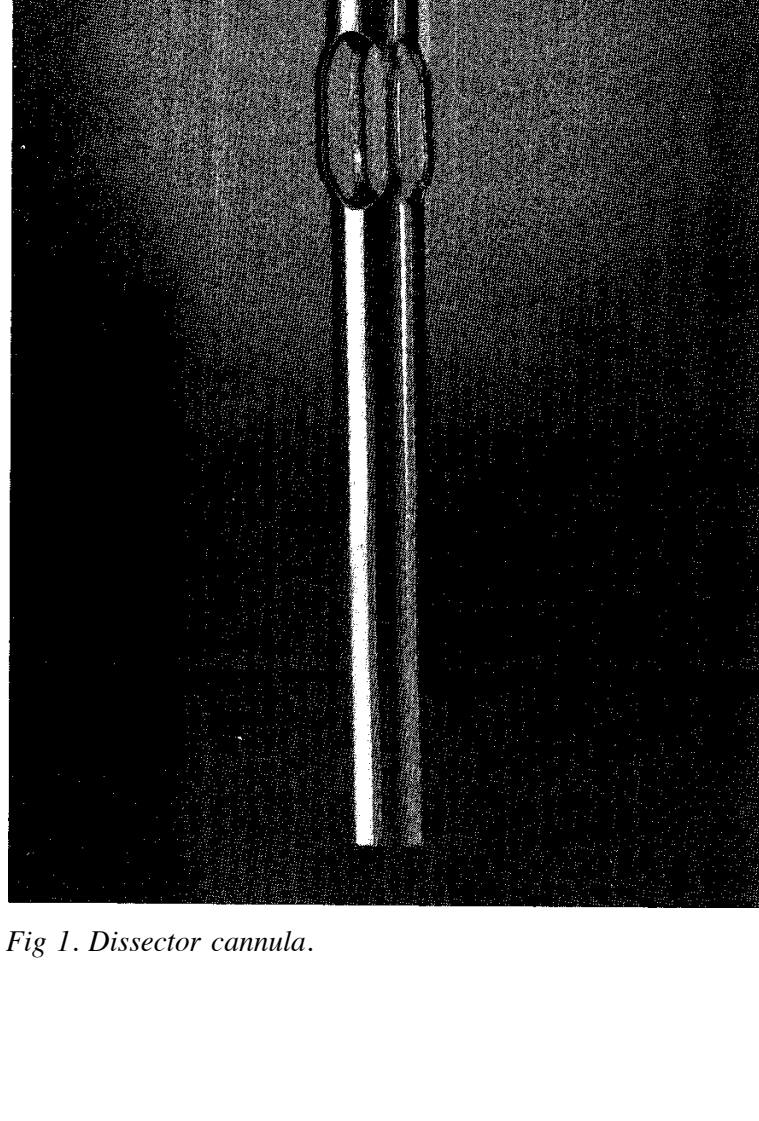


Fig 1. Dissector cannula.

Gadgetry: Becker: Treating Gynecomastia

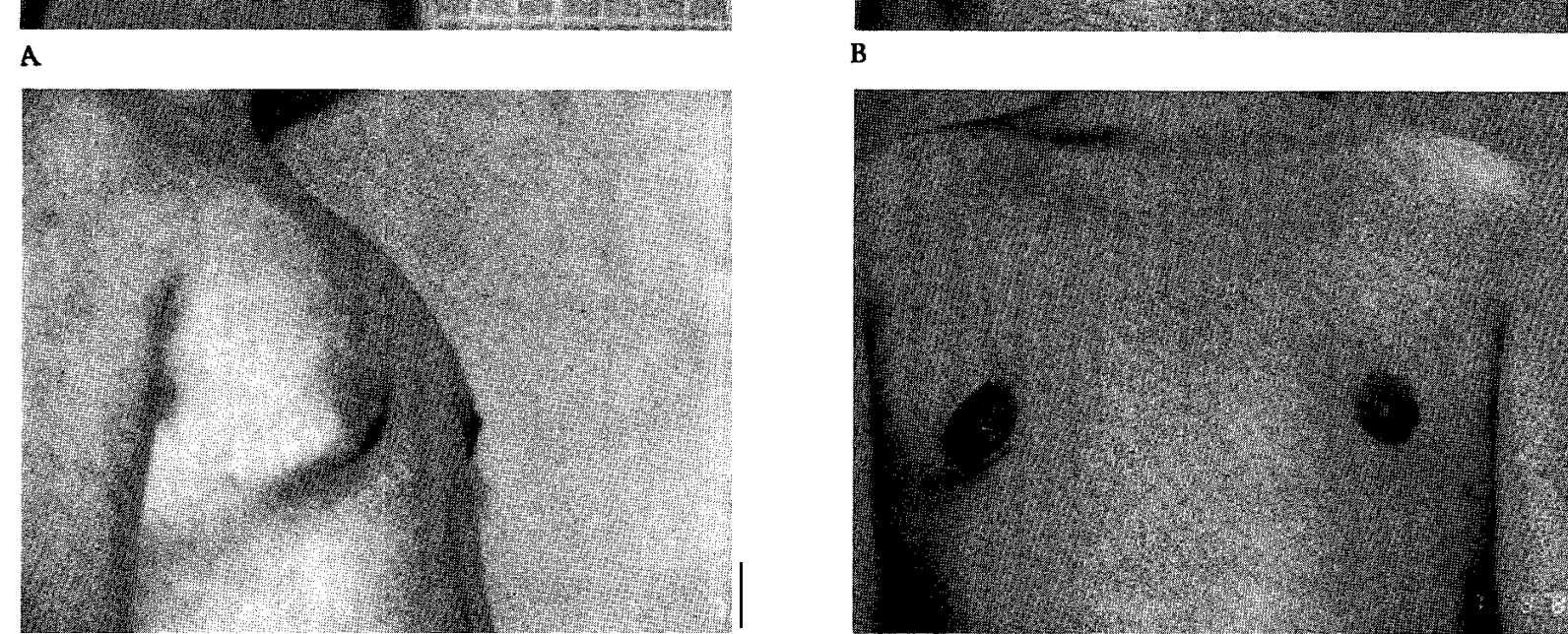
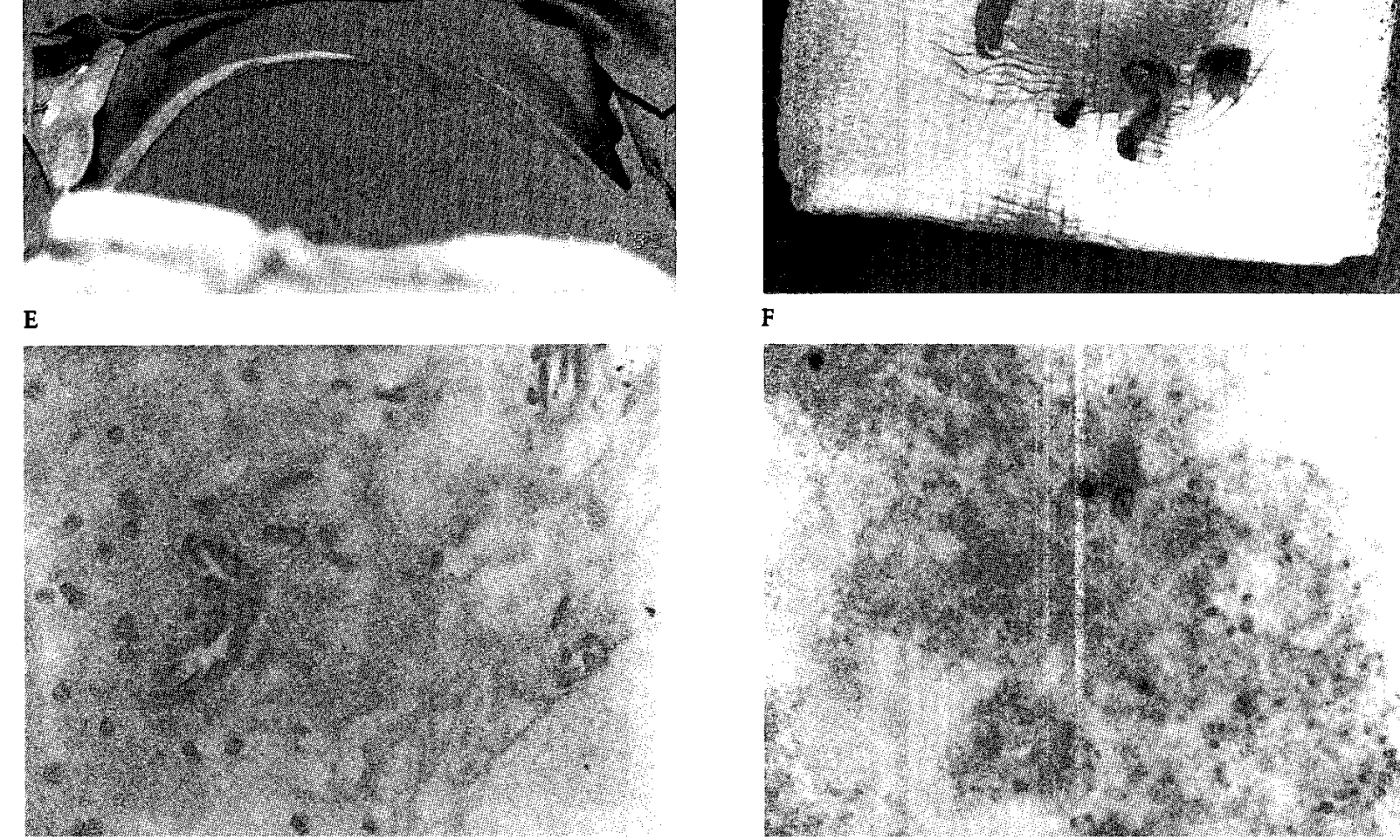


Fig 2. (A,B) A 24-year-old man with marked gynecomastia. (C,D) Postoperative result—no sharp resection performed. (E) Difference between left and right breast noted following suctioning of right breast. (F) Breast tissue fragments aspirated with cannula. (G,H) High- and low-power magnification of sections showing breast tissue.

381

Annals of Plastic Surgery Vol 24 No 4 April 1990



G H
Fig 2. Continued

382

Gadgetry: Becker: Treating Gynecomastia

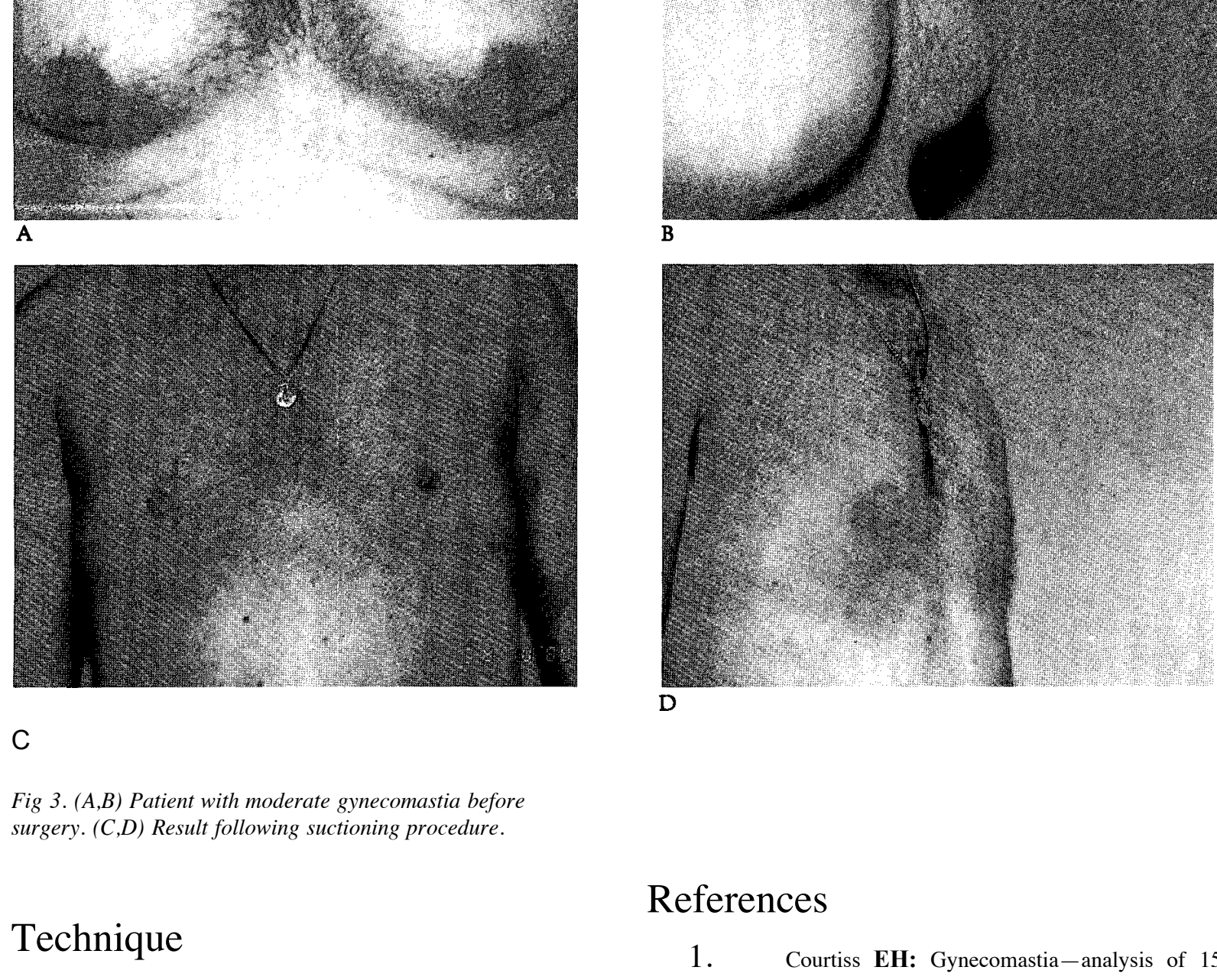


Fig 3. (A,B) Patient with moderate gynecomastia before surgery. (C,D) Result following suctioning procedure.

Technique

The breast is infiltrated with a solution of dilute lidocaine with epinephrine and saline. A small incision is made at the areolar margin or the axillary area (a 4-mm and a 6-mm cannula are used). Suctioning of the fatty tissue is carried out initially with relative ease. Care is taken to feather the dissection beyond the breast margin and inframammary fold.

At this stage the residual breast tissue is grasped in one hand, and the cannula is whisked back and forth through the breast tissue with the other hand until sufficient resection of the breast tissue has been obtained. At the completion of the procedure the incision is closed and a compressive dressing applied.

References

1. Courtiss EH: Gynecomastia—analysis of 159 patients and current recommendations for treatment. *Plast Reconstr Surg* 79:740-753, 1987
2. Lewis L: Lipoplasty as an adjunctive treatment for gynecomastia. In Hetter G. (ed). *Lipoplasty*. Boston, Little, Brown, 1984
3. Niladick RA: Lipoplasty as an adjunctive procedure. *Perspect Plast Surg J* 3:21-43, 1989
4. Rosenberg GS: Gynecomastia—suction lipectomy as a contemporary solution. *Plast Reconstr Surg* 80:879-886, 1987

383