



# Breast Reconstruction with the Adjustable Breast Implant

# 3

Hilton Becker

## Introduction

The use of tissue expanders has become the most common technique of performing breast reconstruction as evidenced by the 2018 ASPS Plastic Surgery Statistics Report [1]. Chedomir Radovan, a great innovator of the 1970s, is credited with the development of the Radovan breast expander for implant-based breast reconstruction. [2] The expander was originally placed under the subcutaneous tissue and above the pectoralis major muscle for delayed reconstruction. This technique evolved over time leading to immediate breast reconstruction facilitated by the placement of the expander in a submuscular position. Adjustable breast implants were developed shortly thereafter by making the injection port detachable. In this fashion, the expander could be converted to an implant [3]. The initial adjustable implant was a single-lumen saline-filled implant with a detachable injection port. The double-lumen implants were subsequently developed to contain varying volumes of silicone gel in the outer chamber (e.g., 25%, 35%, 50%) with the purpose to provide the implant a more gel-like feel (Fig. 3.1) [4–6]. The Becker 50-50, which contains 50% silicone gel in the outer chamber, is most commonly used for immediate breast reconstruction.

Adjustable implants were originally used for one-stage delayed breast reconstruction. The implant was placed in a complete subpectoral pocket, where the muscle and overlying skin flaps were serially expanded by injecting saline into the injection port. Once the desired volume is obtained, the injection port is removed, leaving the saline-filled implant as

the definitive implant. With immediate reconstruction, to facilitate expansion, the muscle can be released along its inferior attachment and elongated with an acellular dermal matrix (ADM) or a synthetic mesh.

With the introduction of skin-sparing and nipple-sparing mastectomies, expansion is rarely necessary. Skin preservation facilitates prepectoral breast reconstruction as the excess skin enables tension-free closure. A full sheet of ADM is commonly used as an adjunct to cover and support the implant to compensate for muscle coverage [7]. Fat grafting can also be used to thicken the skin flap, reducing the need for ADM and thus significantly reducing the cost of reconstruction [8].

Adjustable implants offer solutions for revision reconstruction and complex cases such as radiation problems with poor wound healing, symmastia, and asymmetry.

## Anatomy

Adjustable breast implants can be placed either posterior (subpectoral) or anterior (prepectoral) to the pectoralis major muscle. The subpectoral plane is the space beneath the pectoralis major in contiguity with the serratus anterior muscle. The pectoralis muscle can be released at its inferior border to enlarge the subpectoral space. The muscle is then reattached to the inframammary fold with a sheet of ADM. The prepectoral space is the space arising beneath the skin flap following the mastectomy. It usually extends into the axilla and laterally to the latissimus dorsi muscle. The base is the pectoralis major and serratus anterior muscles.

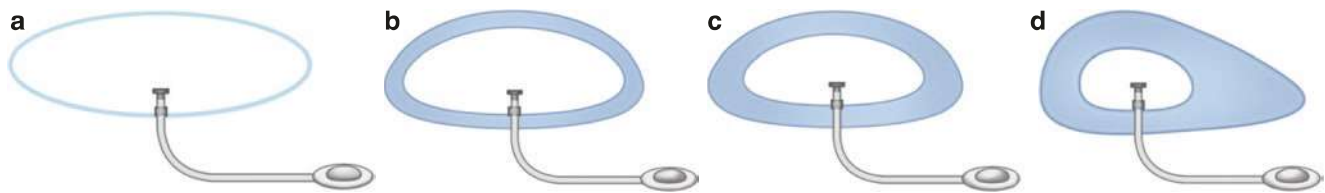
## Patient Selection

Almost all patients referred to us for immediate reconstruction are usually eligible for breast reconstruction with adjustable implants. Circulation to the skin flaps is not usually assessed with angiography since even patients with suboptimal circulation can be included.

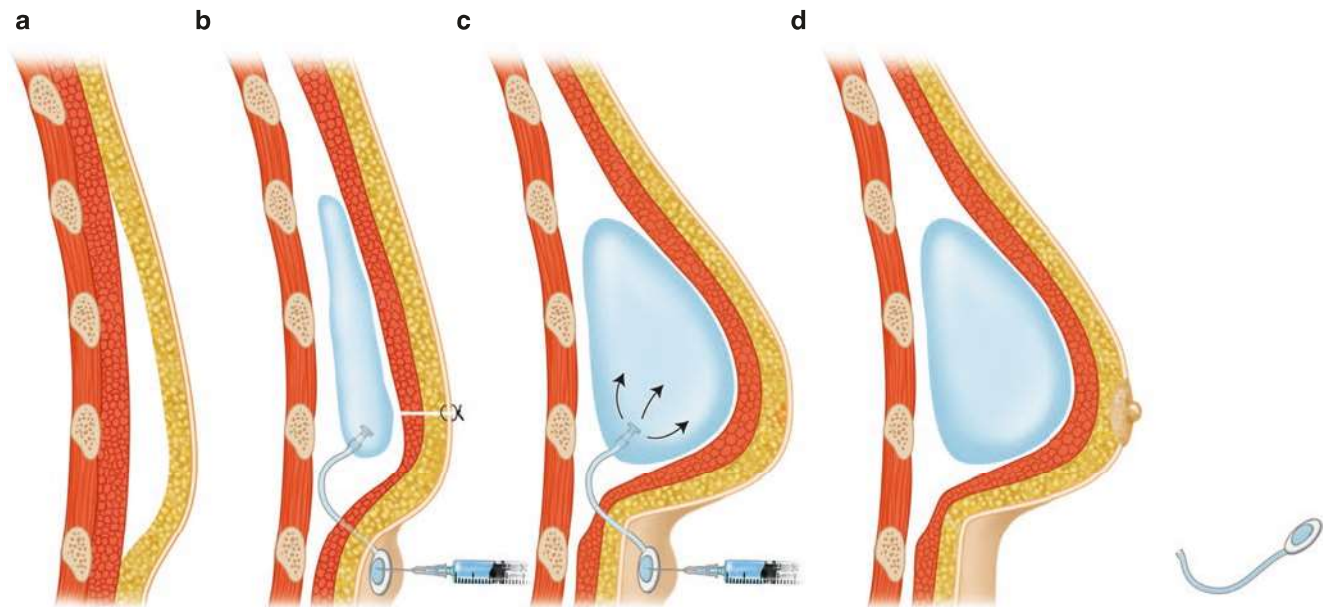
**Electronic Supplementary Material** The online version of this chapter [https://doi.org/10.1007/978-3-030-34603-4\\_3](https://doi.org/10.1007/978-3-030-34603-4_3) contains supplementary material, which is available to authorized users.

H. Becker (✉)  
Clinic of Plastic Surgery, Boca Raton, FL, USA

Department of Surgery, Florida Atlantic University and Department  
of Plastic Surgery, Cleveland Clinic Florida, Weston, FL, USA  
e-mail: [Hilton@beckermd.com](mailto:Hilton@beckermd.com)



**Fig. 3.1** Adjustable breast implants: (a) single-lumen saline; (b) 25% silicone gel; (c) 50% silicone gel; and (d) anatomical



**Fig. 3.2** (a) Following mastectomy; (b) adjustable implant placed beneath the muscle; (c) further saline added to expand the flap; and (d) injection port removed

Patients with advanced disease or large tumors extending to the muscle are excluded and usually require autologous reconstruction.

## Preoperative Planning

The skin incisions are marked by the oncological surgeon together with the plastic surgeon. A decision is made as to the type of mastectomy to be performed (e.g., skin-sparing or nipple-sparing mastectomy). Incision placement is based on the size of the breast, tumor location, degree of ptosis, and whether the nipple will be preserved. The inframammary incision is preferable in smaller-breasted patients. A vertical incision is used in larger or ptotic breasts.

If the nipple is to be removed, in smaller-breasted patients, a circumareolar incision with lateral extension is used, whereas in patients with larger breasts or ptosis, a vertical incision is used [9–11]. A wise pattern is not used in the first stage in order to avoid compromising the nipple areola complex. In cases of moderate ptosis, the vertical incision is deepithelized laterally and the dermal flap is advanced medially, thus lifting the lower pole [12]. Further elevation is achieved by allowing the flap to contract postoperatively over an underfilled implant [12, 13]. In this way, skin contraction

reduces the need for mastopexy with skin excision at the time of the initial reconstruction [14]. Further nipple elevation can be achieved during a secondary procedure if necessary.

Depending on the circulation and thickness of the flaps, the appropriate implant is selected. In cases where delayed reconstruction may be considered (e.g., if the skin flaps are thin or circulation threatened), the smooth single-lumen adjustable implant (Spectrum) is used as a spacer. Alternatively, the Becker 25 can be used. In cases where a direct-to-implant breast reconstruction is being considered, the smooth Becker 50-50 is the preferred choice.

## Surgical Technique

For delayed reconstruction, the adjustable implant can be placed submuscularly or above the muscle. When placed submuscularly, the pocket is dissected using fiberoptic retraction. A temporary saline breast implant sizer (Mentor Corp., Santa Barbara, CA) is placed in the pocket and overexpanded to assess the pocket. The sizer is then removed, and the adjustable implant is placed in the pocket with the desired volume of saline. A smooth surface is preferable for an adjustable implant as it is softer and more elastic and ripples less. The injection port is placed in a

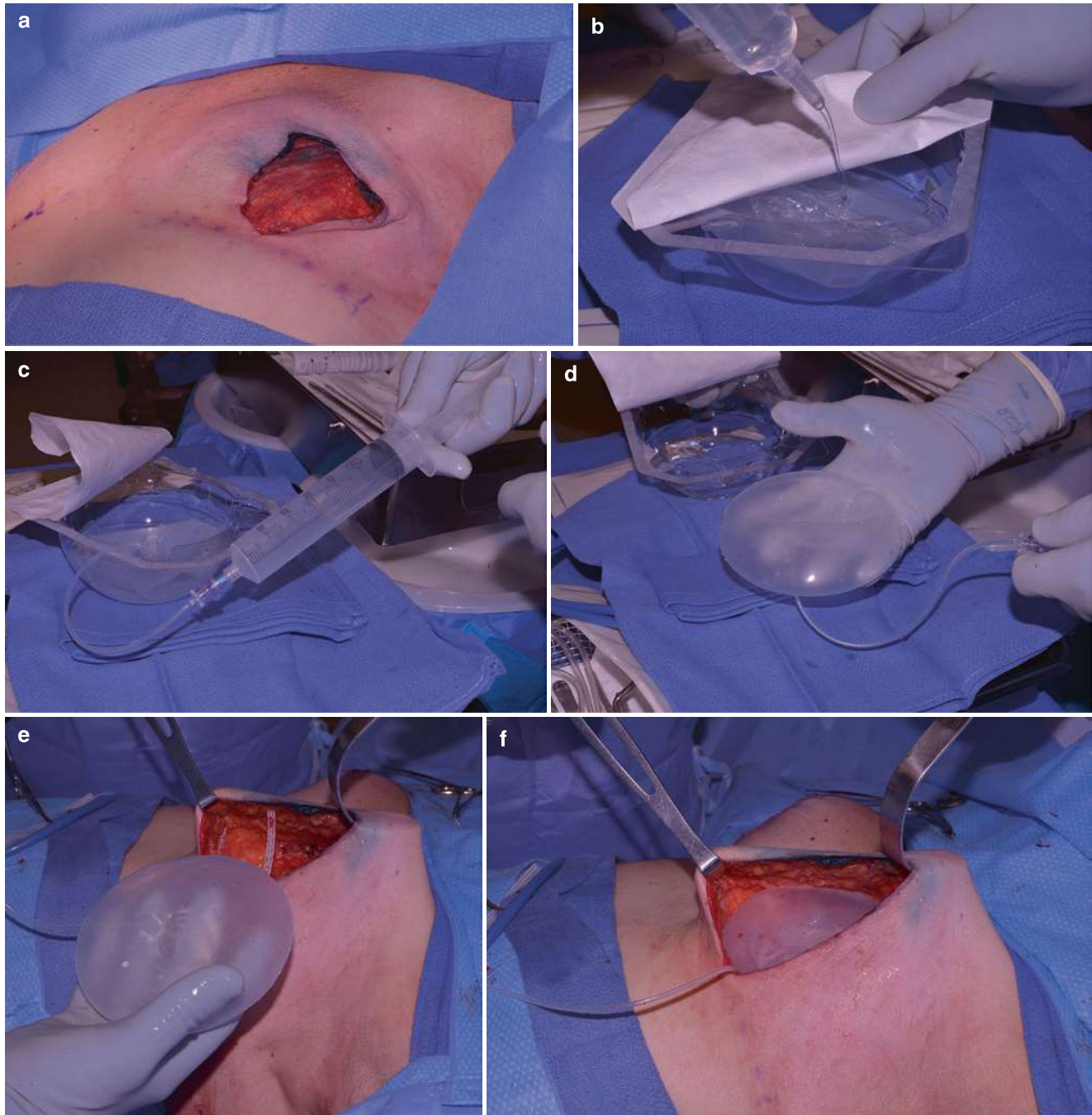
subcutaneous pocket and sutured into position. The muscle layer is sutured, followed by skin closure (Fig. 3.2).

For immediate reconstruction, the adjustable implant is usually placed above the muscle. In order to place the implant in the correct position, the prepectoral space is adjusted appropriately. The lateral skin flap is advanced medially and sutured to the chest wall beneath the pectoralis muscle with 1 or 2 rows of interrupted 2.0 polyglactin sutures (Vycril®, Ethicon, Somerville, NJ). A temporary saline breast implant sizer is then placed in the pocket and overexpanded. The pocket is assessed, the sizer is removed, and the pocket is

adjusted as necessary. If the flap is sufficiently thick, no ADM is used. If the flap is thin, especially with nipple sparing mastectomies, an anterior layer of ADM (FlexHD Pliable MTF Biologics Edison NJ) is used to cover the anterior surface of the implant.

The adjustable implant package is opened, and the implant is irrigated with a triple antibiotic solution. Once the appropriate amount of air is removed, the implant is placed in the pocket (Fig. 3.3).

The adjustable implant comes packaged with two differently sized injection ports: one large and one small. It is the



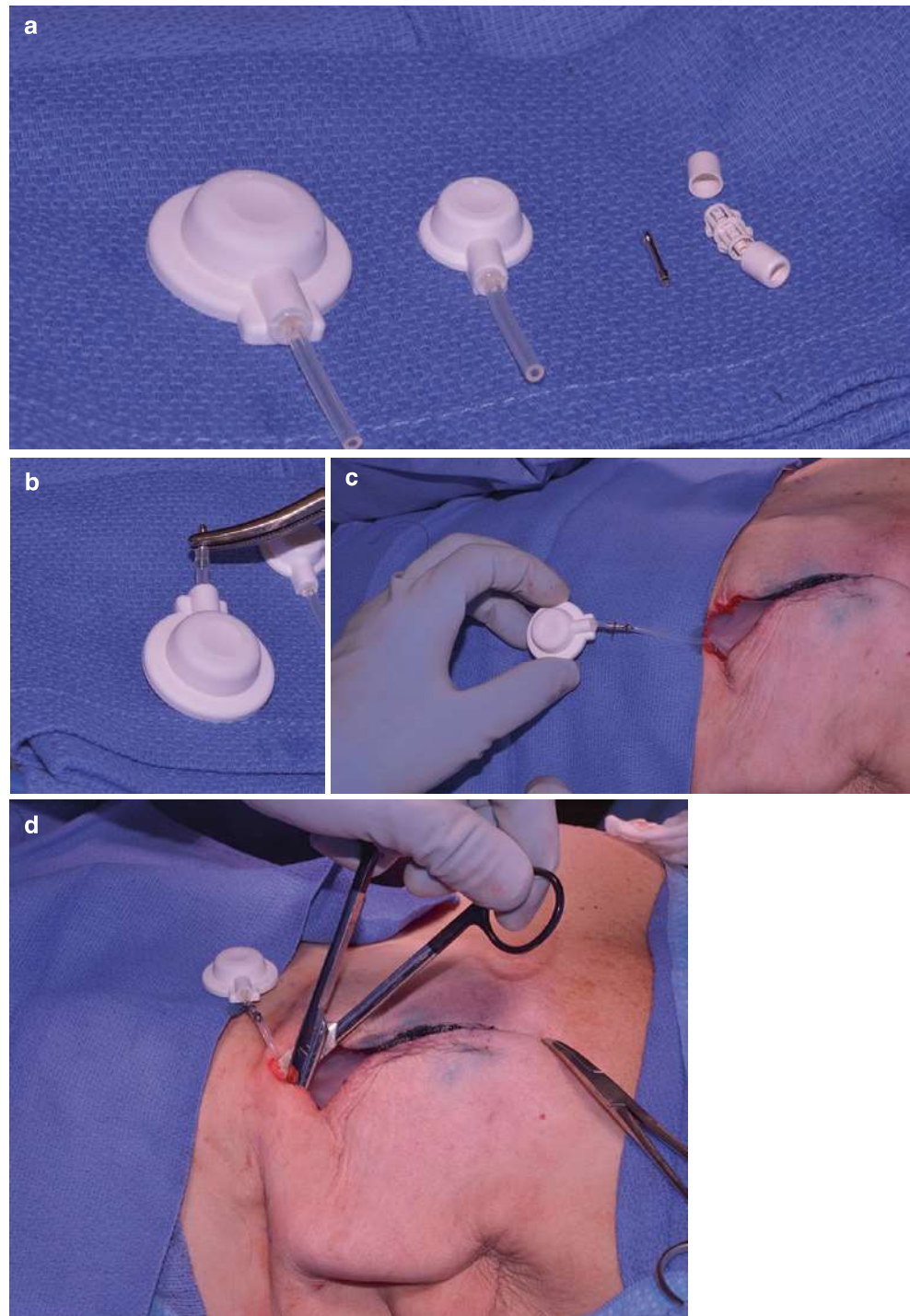
**Fig. 3.3** (a) Following skin-sparing mastectomy; (b) implant irrigated with antibiotic solution; (c) air is partially removed from the implant; (d) partially air-filled implant; (e, f) the implant is placed in the pocket

surgeon's personal choice as to which size to use, depending on the size of the patient and thickness of the flaps. There are also two different connectors: a plastic clip-on connector, which is more difficult to use and requires dissection in order to free it on removal, and a steel connector that requires suture fixation with 3.0 silk sutures (Perma-hand®, Ethicon, Somerville, NJ). The advantage of this connector is that the tubing on the injection port can be shortened prior to attachment to the implant fill tube. The injection port is placed in a

pocket dissected subcutaneously, usually lateral to the incision, and secured in position with interrupted 3.0 polyglactin sutures (Fig. 3.4). On removal, the injection port can be retrieved by grasping the fill tube beyond the connector, thus avoiding disruption at the connection. Once removed, the implant seals at the self-sealing valve (Fig. 3.5).

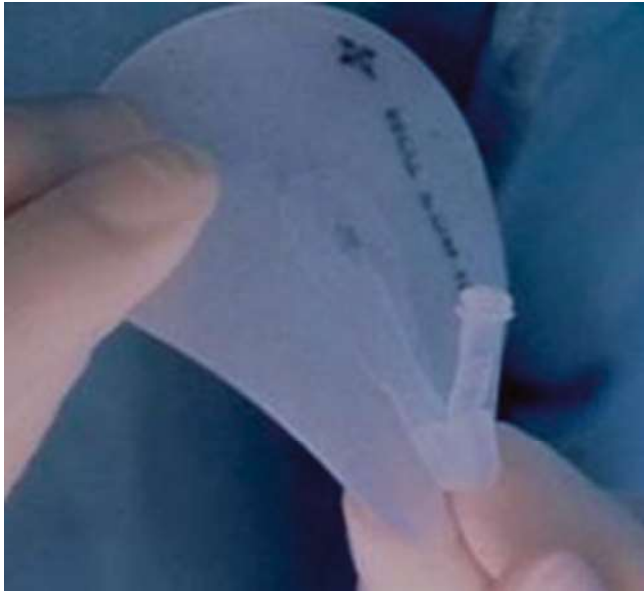The pocket is once again irrigated with triple antibiotic; one or two drains are placed through a long subcutaneous tunnel and sutured to the skin. The incision is closed with a deep row of

**Fig. 3.4** (a) Different injection ports with steel and plastic connectors; (b) steel connector inserted; (c) a 3.0 silk tie is tied around each end of the connector; and (d) pocket is made for injection port



interrupted 3.0 polyglactin sutures followed by 2 rows of 4.0 running poliglecaprone sutures (Monocryl®, Ethicon, Somerville, NJ). It is important that closure be completely tension free and water tight. Transparent film dressings (Tegaderm®, 3M, Maplewood, MN) are used to help hold the flap in position and then further reinforced with gauze and tape.

When the implant is used as a spacer, it is placed virtually empty, containing only a small amount of air in order to maintain the implant shape (Video 3.1). Postoperatively, once circulation is assured, further air is injected using a 0.20 µm bacterial syringe filter (Cole-Parmer, Chicago, IL).



**Fig. 3.5** Self-sealing valve

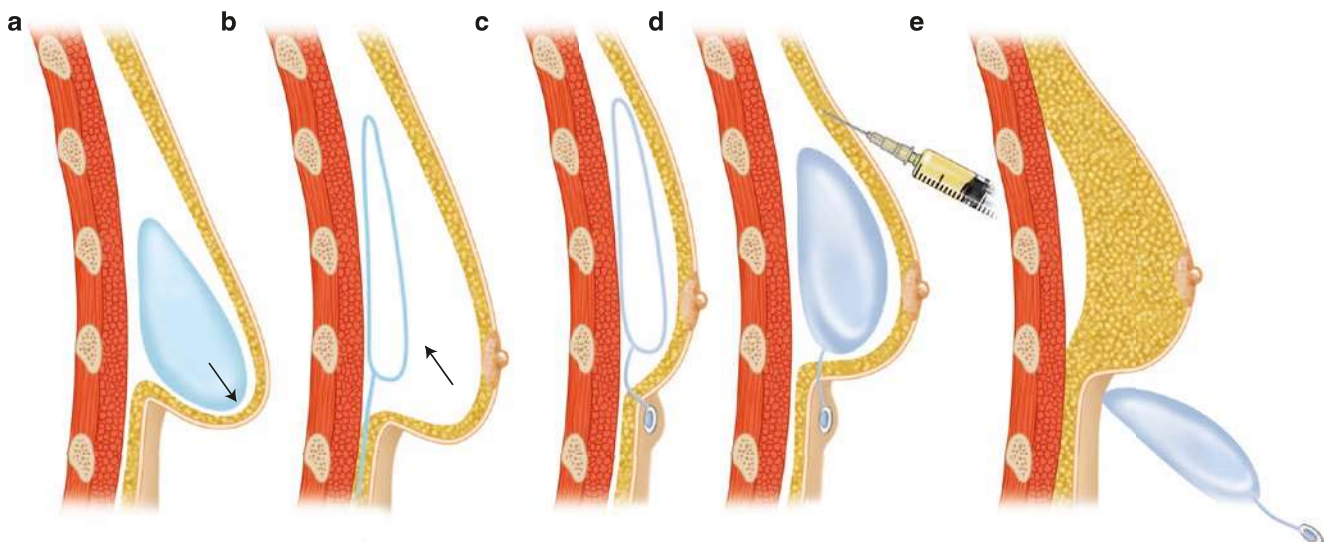
An implant that is underfilled with saline ripples and collapses to the bottom of the mastectomy pocket, resulting in pressure on the inferior pole. We therefore currently underfilled the implant initially with air. This results in a lighter, more uniform surface that does not collapse and exerts less pressure on the lower pole. Furthermore, underfilling the implant with air allows the flap to contract, thicken, and elevate. Fat grafting can also be performed to thicken the flap further, thus virtually eliminating the need of ADM in immediate reconstruction (Fig. 3.6) [12].

If improved soft tissue coverage is desired, further fat is grafted, and the volume of the implant is reduced. Ultimately, sufficient fat can be grafted, enabling removal of the implant and resulting in a total autologous reconstruction. As an additional benefit, the patient is spared the anguish of having a deformed breast during the prolonged fat-grafting procedure without an implant.

The manufacturer of the adjustable implants specifies fill volumes on the instruction brochure. These volumes are not clinically validated. There are however valuable indications for deviating from these volumes (e.g., placing the implant underfilled initially and overfilling if necessary) for symmetry or to correct capsular contracture [15]. Patients are always informed and give consent for off-label use.

### Postoperative Care

As the adjustable implant is a dynamic implant, frequent postoperative care is necessary in order to take advantage of adjustability. The patient is seen the day after surgery. All



**Fig. 3.6** (a) Saline-filled implant collapses at the bottom of the mastectomy pocket, and its weight causes pressure on the flap and sagging; (b) implant underfilled with air fills the upper pole of the mastectomy pocket, acts as a spacer, and avoids pressure on the flap; (c) flap con-

tracts, thickens, and elevates; (d) air is replaced with saline and fat grafting is used to thicken the flap further; and (e) implant is removed resulting in an autologous reconstruction

dressings are taken down with the patient in the standing position. The position of the implant, and the circulation of the flaps are assessed. Volume may be reduced if there is any concern about circulation. The patient is seen 2 days later, at which stage further adjustments are made.

If the implant is in good position and circulation intact, air may be removed and replaced with saline injected into the injection port using a 23 g butterfly needle. If the implant is sitting too low, further air is injected with a 50 cc syringe attached to a bacterial filter, and an inferior pressure strap is applied. On the contrary, if the implant is too high, saline is added, and a superior strap is applied. The pressure of the strap and the weight of the saline-filled implant will facilitate lowering of the implant. The implant may also be temporarily overexpanded to obtain more ptosis. The patient is then seen every few days, and further saline is added as needed. When the correct size is obtained, the patient is scheduled for removal of the injection port, usually 3–12 months later.

In cases where radiation is required, the volume of the implant can be adjusted to satisfy the needs of the radiation therapist. Furthermore, the implant can be overexpanded soon after radiation before scarring sets in, thus reducing capsular contracture. In the event that an open capsulotomy is needed, the adjustable implant can be overexpanded for several weeks following the capsulotomy. This helps reduce the recurrence of capsular contracture.

Immediate breast reconstruction has a high complication rate [16]. High-risk cases are usually delayed for secondary reconstruction or immediate delayed reconstruction [17]. Alternatively, the smooth adjustable implant can be placed underfilled functioning as a spacer, thus greatly reducing the risk of flap ischemia and extrusion of the implant.

There is a definite learning curve in using adjustable implants; however, when correctly used, complications are relatively uncommon. In fact, the adjustable implants often help avoid complications such as asymmetry and capsular contracture. Complications specific to the adjustable implant include rippling, seroma, skin erosion, premature pocket closure, valve failure, and injection port problems. Rippling is usually more common with the saline adjustable and textured implants. If the incorrectly sized implant has been selected, and it is necessary to lower the volume, rippling occurs, usually requiring replacement with a gel implant. Erosion through skin flaps has been seen in cases where a textured implant is underfilled and forms a fold that can cause irritation to thin skin flaps and eventually erode. Premature pocket closure can also occur if the implant has been left underfilled for too long. Valve failure is very uncommon, yet has been seen where the injection port has been left in for excessively long periods of time. Injection port problems such as rotation, which can lead to kinking of the fill tube, and infection, if the port is placed too close to the skin, have also been described.

## Clinical Cases

### Case 1

A 46-year-old patient with right-sided breast carcinoma underwent bilateral skin-sparing mastectomy. Reconstruction was performed with a smooth Becker 50-50 silicone gel implant. The implant was placed in a subpectoral pocket and partially filled with saline via a closed system. The muscle was released and reinforced with an ADM. The injection port was placed lateral to the incision. Once circulation was assured 2 days postoperatively, further saline was added. The injection ports were removed at 6 months, and the nipples were reconstructed (Fig. 3.7).

### Case 2

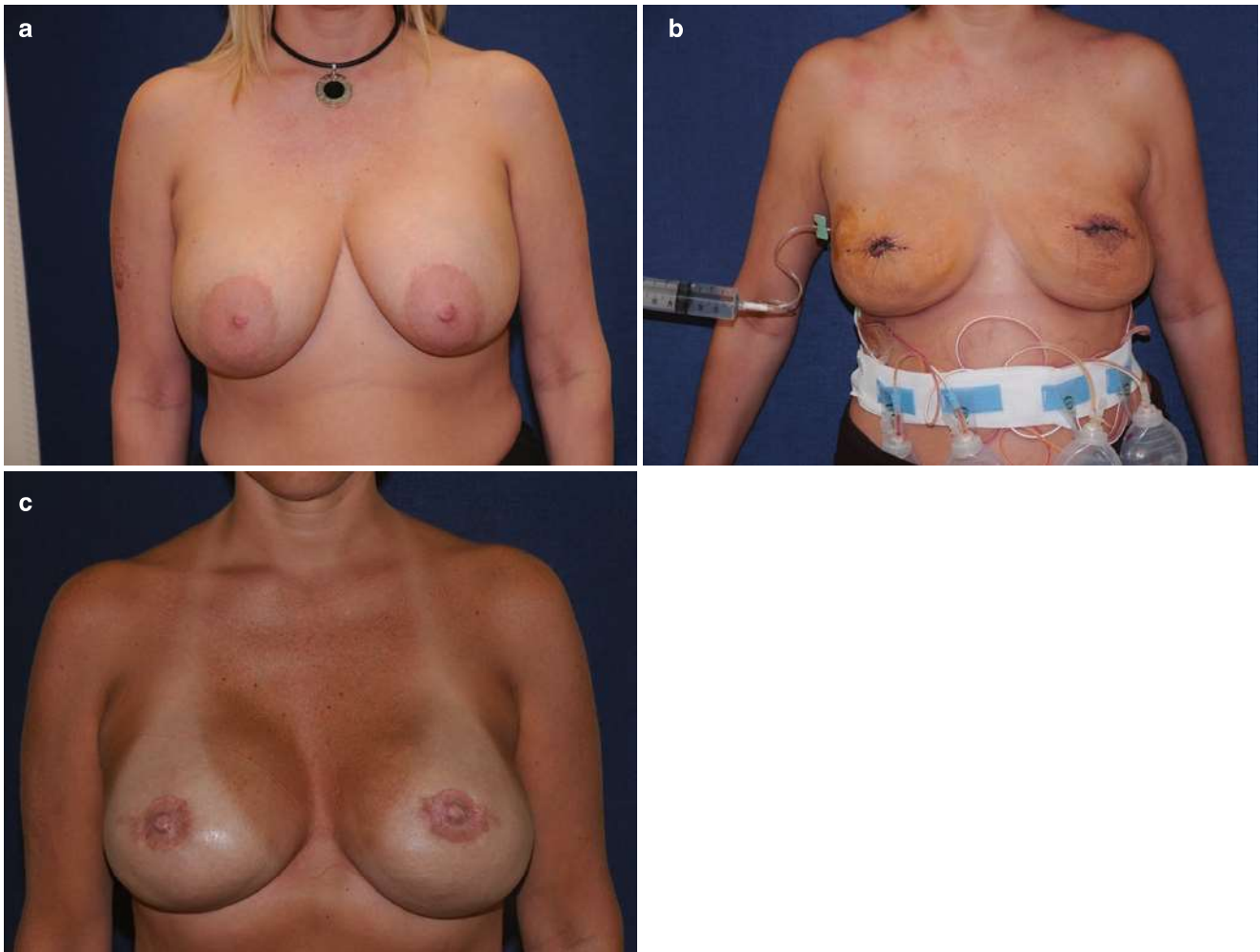
A 50-year-old patient presented with carcinoma of the right breast. Following bilateral nipple-sparing mastectomy, an adjustable implant was placed prepectoral with full ADM coverage. The injection port was placed in a subcutaneous pocket. The incision was closed tension free. Further saline was added postoperatively until the correct size was obtained. The patient showed good symmetry with no animation deformity (Fig. 3.8).

### Case 3

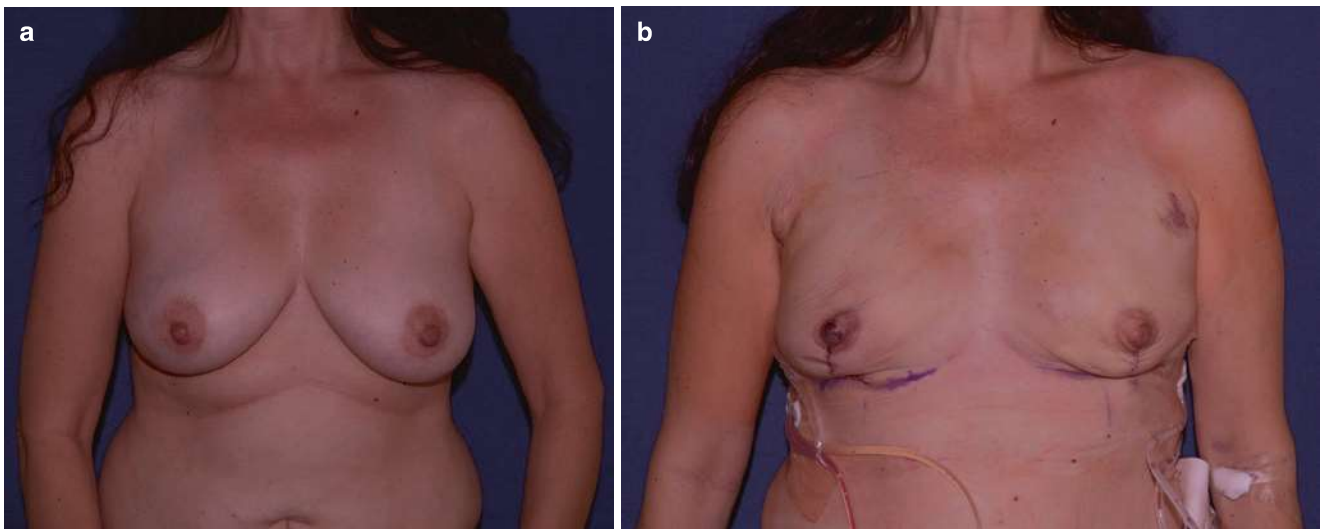
A 43-year-old female, BRCA-positive with large, ptotic, asymmetrical breasts, underwent bilateral nipple-sparing mastectomy with vertical incision and reconstruction with prepectoral Spectrum implants initially filled with 100 cc of air. No ADM was used, and the breasts were taped into position to encourage contraction. Good symmetry was achieved without performing a mastopexy. The patient subsequently underwent conversion to silicone gel implants (Fig. 3.9).

### Case 4

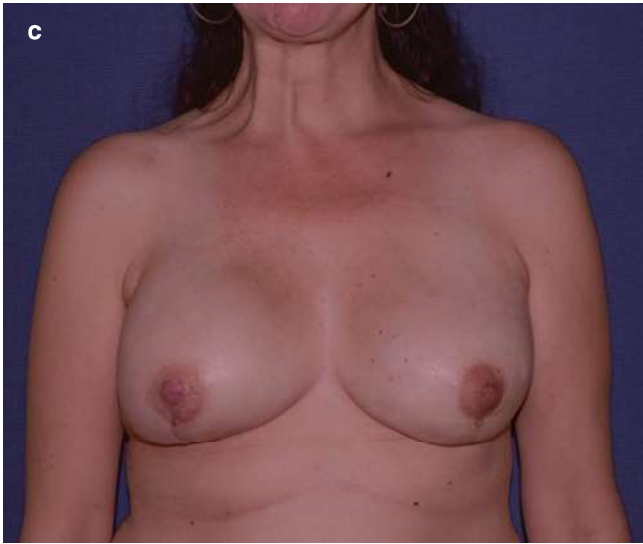A 38-year-old patient with carcinoma of the right breast underwent bilateral nipple-sparing vertical incision mastectomy. An adjustable implant was placed prepectoral and initially partially filled with air. The air subsequently replaced with saline. Skin flaps were allowed to contract, and fat grafting was performed. The volume of the implants was reduced, and further fat grafting was then performed. The implants were finally removed. The final result exhibited soft and mobile breasts (Figs. 3.10).



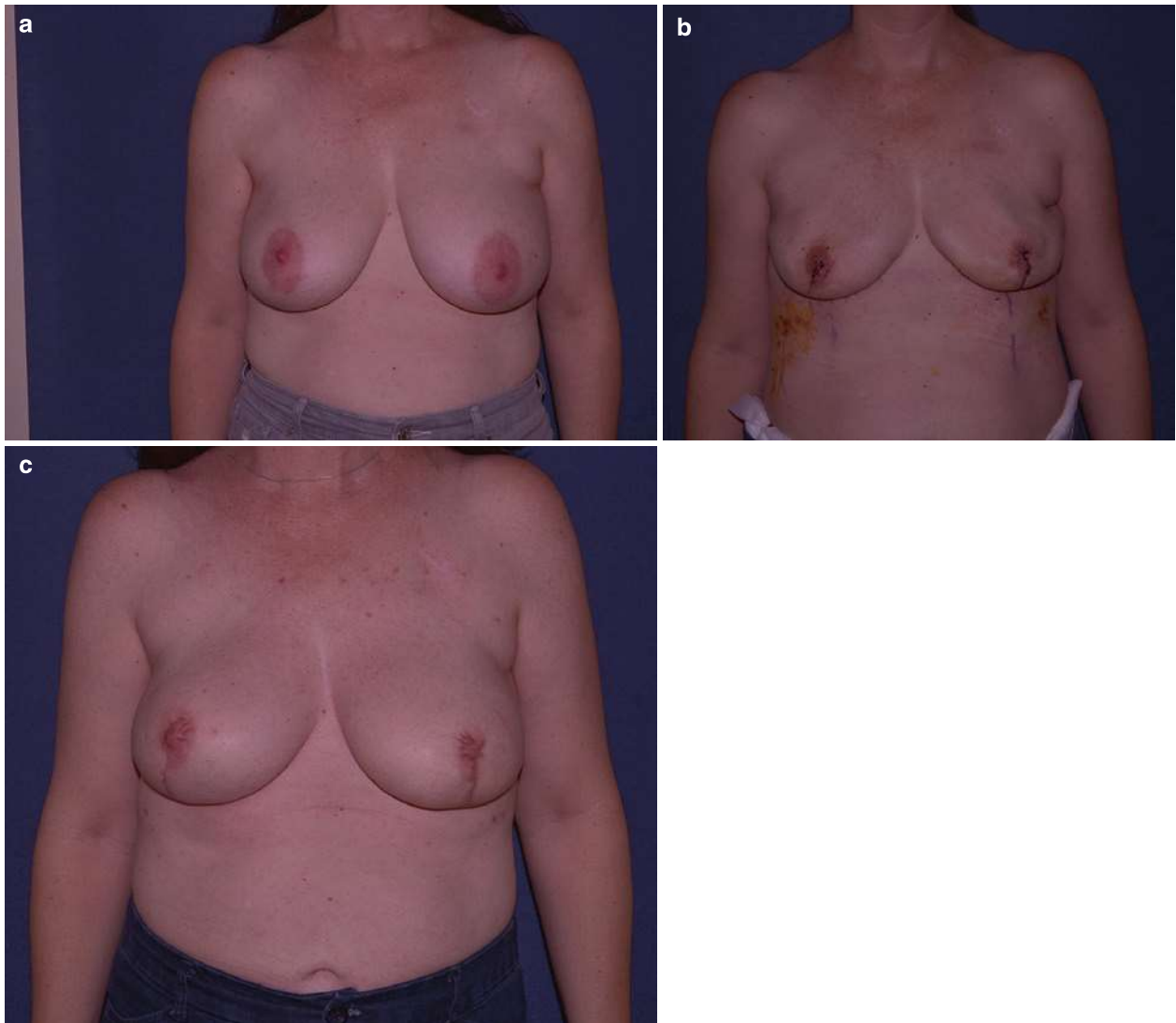
**Fig. 3.7** (a) Preoperative view; (b) implant being filled postoperatively; and (c) late postoperative view after removal of injection port and nipple reconstruction



**Fig. 3.8** (a) Preoperative view; (b) immediate postoperative view; and (c) long-term postoperative view

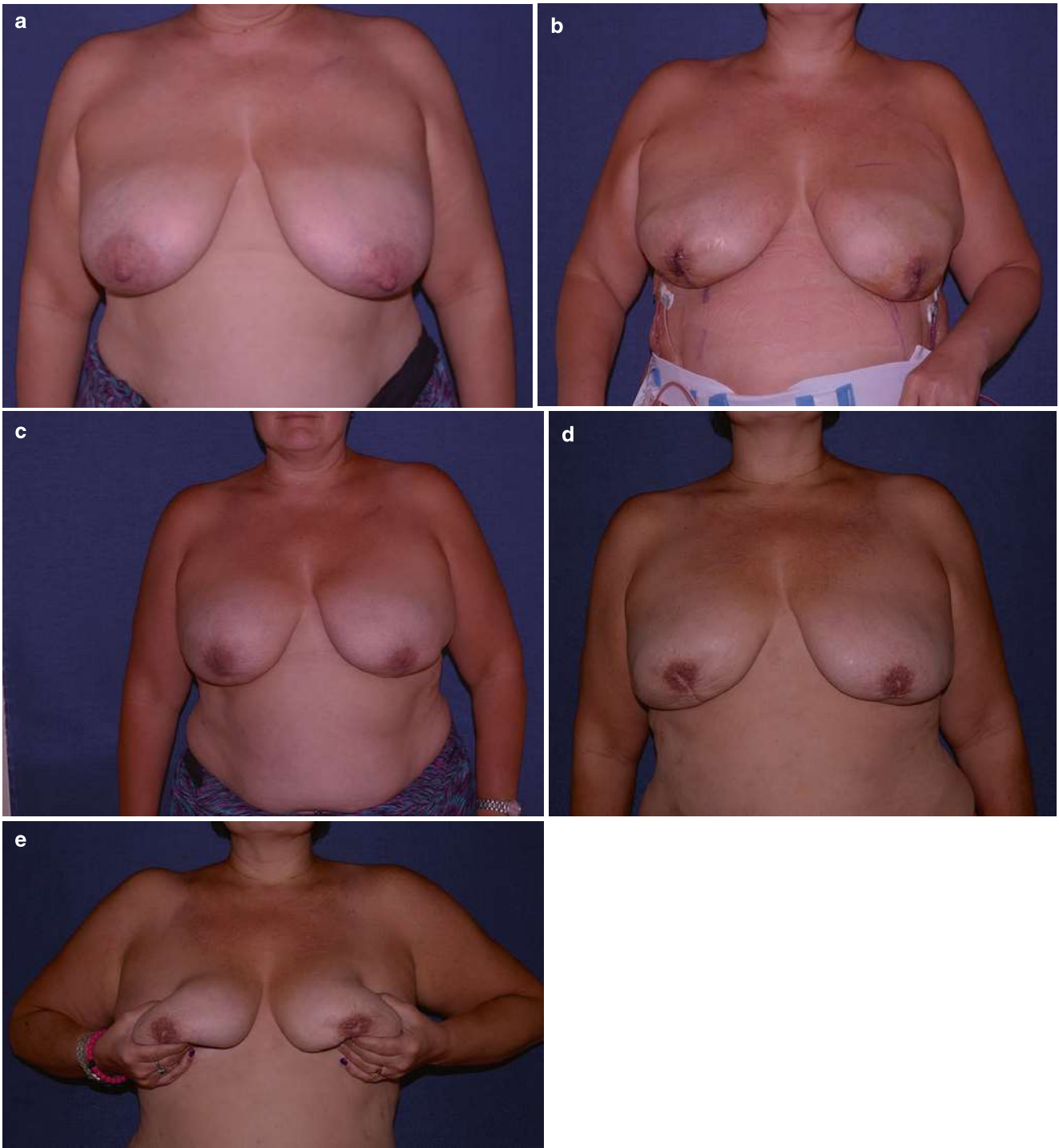

**Fig. 3.8** (continued)



**Fig. 3.9** (a) Preoperative view; (b) immediate postoperative view; and (c) long-term postoperative view





**Fig. 3.10** (a) Preoperative view; (b) immediate postoperative view; (c) view after multiple sessions of fat grafting; (d, e) final result after implant removal

## Conclusion

The use of adjustable implants has evolved from delayed to immediate reconstruction and more recently from submuscular to prepectoral implementations. The adjustable implant expands the range of patients that are suitable for immediate prepectoral implant reconstruction by reducing pressure on the skin flaps. Underfilling an adjustable implant with air allows the skin flaps to contract and thicken, reducing the need for ADM coverage. Adjustable implants are beneficial in revision cases and correction of implant complications. In this fashion, better symmetry, with reduced surgical time and cost, is achieved.

**Disclosure** Dr Becker is a consultant for Mentor Corp. and Surgical Innovation Associates.

## References

1. American Society of Plastic Surgeons. Plastic surgery statistics report. 2018. Available at <http://www.plasticsurgery.org/News-and-Resources/2018-Statistics.html>. Accessed 15 Apr 2019.
2. Radovan C. Breast reconstruction after mastectomy using the temporary expander. *Plast Reconstr Surg*. 1982;69:195–208.
3. Becker H. Breast reconstruction using an inflatable breast implant with detachable reservoir. *Plast Reconstr Surg*. 1984;73:678–83.
4. Becker H. The permanent tissue expander. *Clin Plast Surg*. 1987;14(3):10–3.
5. Becker H. The expandable mammary implant. *Plast Reconstr Surg*. 1987;79(4):631–7.
6. Becker H, Maraist F. Immediate breast reconstruction after mastectomy using a permanent tissue expander. *South Med J*. 1987;80(2):154–60.
7. Becker H. One stage immediate breast reconstruction with adjustable implants. In: Spear SL, editor. *Surgery of the breast*, vol. 1. Philadelphia: Lippincott, Williams and Wilkins; 2006.
8. Spear SL, Pelletiere CV, Lockwood M. Immediate breast reconstruction with tissue expanders and AlloDerm. In: Spear SL, Wiley SC, Robb GL, Hammond DC, Nahabedian MY, editors. *Surgery of the breast: principles and art*. Philadelphia: Lippincott Williams & Wilkins; 2006. p. 484–8.
9. Zienowicz RJ, Karacaoglu E. Implant-based breast reconstruction with allograft. *Plast Reconstr Surg*. 2007;120:373–81.
10. Sbitany H, Piper M, Lentz R. Prepectoral breast reconstruction: a safe alternative to submuscular prosthetic reconstruction following nipple-sparing mastectomy. *Plast Reconstr Surg*. 2017;140(3):432–43.
11. Vidya R, Iqbal FM. A guide to prepectoral breast reconstruction: a new dimension to implant-based breast reconstruction. *Clin Breast Cancer*. 2017;17(4):266–71.
12. Becker H, Lind JG 2nd, Hopkins EG. Immediate implant-based prepectoral breast reconstruction using a vertical incision. *Plast Reconstr Surg Glob Open*. 2015;3(6):e412.
13. Becker H, Zhadan O. Filling the spectrum expander with air—a new alternative. *Plast Reconstr Surg Glob Open*. 2017;6:e1541.
14. Becker H, Zhadan O. Tissue contraction—a new paradigm in breast reconstruction. *Plast Reconstr Surg Glob Open*. 2018;6:e1865.
15. Becker H, Carlisle H, Kay J. Filling of adjustable breast implants beyond the manufacturer's recommended fill volume. *Aesthet Plast Surg*. 2008;32(3):432–41.
16. Jagsi R, Jiang J, Momoh AO, et al. Complications after mastectomy and immediate breast reconstruction for breast cancer: a claims-based analysis. *Ann Surg*. 2016;263(2):219–27.
17. Zenn MR. Staged immediate breast reconstruction. *Plast Reconstr Surg*. 2015;135(4):976–9.