

Free Nipple Graft Breast Reduction without a Vertical Incision

Oscar Adrian Vazquez, MD, MS
 Payton Yerke Hansen, BS
 Jacob Komberg, BS
 Hanna L. Slutsky, BS
 Hilton Becker, MD, FACS, FRCS

Background: A technique of a free nipple graft with an inframammary incision and no vertical incision offers promising postoperative results as a safe and aesthetic alternative.

Methods: This was a retrospective chart review of patients who presented to a single surgeon for breast reduction surgery using a free nipple graft with an inframammary incision from June 1999 to March 2021. Baseline patient demographics and clinical information along with postoperative complications were recorded and compared between patients who presented for concomitant reconstruction or just reduction. A narrative literature review on surgical techniques and outcomes was also conducted.

Results: From the literature search, there have been minimal prior mentions of breast reductions using a free nipple graft with an inframammary incision and no vertical incision. Fifty-five cases were identified for breast reduction surgery in the author's 22-year study period, of which 46 had adequate clinical documentation and follow-up. An estimated 22 patients had either both or one breast reconstructed with opposite side breast reduction, and 24 patients underwent breast reduction alone with free nipple grafting. No implants were used in any of the patients.

Conclusions: The free nipple graft technique with an inframammary incision can be performed on patients with excessively large or ptotic breasts. It is possible to reduce the volume of the breast and obtain good projection with this method. Furthermore, avoidance of the vertical incision reduces breakdown at the T-junction and is aesthetically beneficial. (*Plast Reconstr Surg Glob Open* 2022;10:e4167; doi: 10.1097/GOX.0000000000004167; Published online 2 March 2022.)

INTRODUCTION

Women with macromastia can have multiple symptoms ranging from intertrigo to chronic back, neck, and shoulder pain, which may hinder their physical function.¹ Common conservative management includes tailored brassieres, weight reduction, and physical therapy. However, these measures are not always effective in alleviating the symptoms and improving patient satisfaction.² When medical management fails, surgical options such as reduction mammoplasty (surgical resection of the breast parenchyma) are considered.³

Reduction mammoplasty involves an anchor or vertical pattern incision with either a superiorly or inferiorly based parenchymal vascular pedicle.^{4,5} The nipple–areolar

complex (NAC) is maintained on the pedicle, but this procedure can prove difficult in larger, ptotic breasts because the pedicle viability may become compromised due to excess length.⁶ Furthermore, if the pedicle is folded or improperly rotated, it can disrupt the underlying vasculature, which can lead to nipple necrosis.⁷ In addition, in rare instances with large reductions using a pedicle, NAC necrosis can happen bilaterally.⁸

To combat the complications of large pedicled reductions, surgeons utilize a free nipple graft with a vertical and inframammary incision on patients with macromastia.⁹ This procedure allows for a more aesthetic breast shape and nipple placement, as well as a decreased risk of vascular disruption. However, the tissue at the T-junction receives a diminished vascular supply, leading to slower tissue healing and an increased risk of wound dehiscence.¹⁰ A benefit to the free nipple graft procedure with no vertical incision is that, in patients with large breasts undergoing lumpectomy for a centrally located breast cancer, the free nipple graft technique allows for aggressive lumpectomy while preserving breast contour.¹¹ The same procedure

From the Department of Surgery, Charles E. Schmidt College of Medicine, Florida Atlantic University, Boca Raton, Fla.

Received for publication November 10, 2021; accepted January 4, 2022.

Copyright © 2022 The Authors. Published by Wolters Kluwer Health, Inc. on behalf of The American Society of Plastic Surgeons. This is an open-access article distributed under the terms of the Creative Commons Attribution-Non Commercial-No Derivatives License 4.0 (CCBY-NC-ND), where it is permissible to download and share the work provided it is properly cited. The work cannot be changed in any way or used commercially without permission from the journal.

DOI: 10.1097/GOX.0000000000004167

Disclosure: Dr. Hilton Becker is a consultant for Marina Medical and Mentor Worldwide, LLC, and Scientific Advisor for Surgical Innovation Associates. All the other authors have no financial interest to declare in relation to the content of this article.

can then be performed on the opposite breast for reduction and symmetry.

The aim of this study was to perform a retrospective chart analysis of healing outcomes of breast reductions using free nipple grafts without a vertical incision. This study is focused on presenting a more aesthetic surgical technique for reduction mammoplasties which warrants further study.

METHODS

Study Design

A retrospective chart review of patients presenting for mammoplasty breast surgery was performed. All patients were seen by a single surgeon and underwent free nipple graft breast reduction with an inframammary incision and no vertical incision from June 1999 to March 2021. Information regarding patient demographics, medical history, surgical materials and technique, and postoperative outcomes was abstracted from provider notes. Written informed consent was obtained from all the patients for their demographic data to be analyzed along with a photograph release for those used. The ethical principles stated in the 2013 Declaration of Helsinki were strictly followed.

Literature Review

For the purpose of this study, a narrative literature review on surgical techniques and outcomes for free nipple graft breast reduction using an inframammary incision was conducted as well. The search was performed using keywords “free nipple graft,” “breast reduction,” “reduction mammoplasty,” “free nipple graft without a vertical scar,” and variations of these terms in PubMed and Google Scholar. Manual searches were also performed by reviewing the references of identified articles and relevant review articles. Articles were excluded if they mentioned the anchor, vertical, or other incisions besides just the inframammary incision or if no free nipple graft was used.

Surgical Technique

The ideal candidates for this procedure are women with large, ptotic breasts who have no intentions of breast feeding postoperatively. There are no breast shape criteria. The procedure can also be used on men with ptotic breast tissue. Furthermore, the procedure is indicated in reduction mastopexy of contralateral breast following mastectomy because a larger amount of breast tissue can be removed, particularly in the subareolar area. It is contraindicated in patients of breast-feeding age.

In the preoperative area with the patients in the upright position, measurements were verified, and markings for the skin incisions extending to the upper edge of the areola for the superior flap were made to maintain the superior pedicle (Fig. 1). The inferior flap was outlined from the inframammary fold to the base of the areola measuring approximately 8–10 cm in width. The patients were prepared and draped in a routine sterile fashion in the supine position under general anesthesia. The bilateral NACs were infiltrated with dilute xylocaine with

Takeaways

Question: The aim of this study was to perform an analysis of healing outcomes and cosmesis of free nipple grafts without a vertical incision to present an aesthetic surgical technique for reduction mammoplasties.

Findings: A retrospective chart analysis with literature review showed that the free nipple graft technique without a vertical incision can be performed on patients with excessively large or ptotic breasts and provides aesthetically pleasing results with decreased incision breakdown.

Meaning: The free nipple graft technique without a vertical incision is an option for breast reductions that merits further investigation.

epinephrine, removed by de-epithelialization, and stored in wet sponges (Fig. 2).

The superior flap was then incised, and dissection was carried out down to the underlying pectoral muscle. The inferior flap was de-epithelialized and maintained with inferior thickness extending to the breast septum (Fig. 3). The excess breast tissue was resected. Hemostasis was obtained. The de-epithelialized dermal flap was sutured to the pectoral muscle with 2-0 interrupted Vicryl sutures. For increased stability, a long-term absorbable mesh can be used to further support the pedicle. Bilateral Jackson-Pratt drains were placed into position. The superior flap was then advanced inferiorly and sutured to the inferior flap with 2-0 interrupted Vicryl sutures (Fig. 4). A #1 Stratafix suture, or #2 Quill, running from medial to central and lateral to central was used at the inframammary fold. The sutures were pulled snug to increase central projection (Fig. 5). This was followed by a 3-0 subcuticular Monocryl suture.

The patients were then placed in a sitting position, and the new locations of the NAC were outlined with methylene

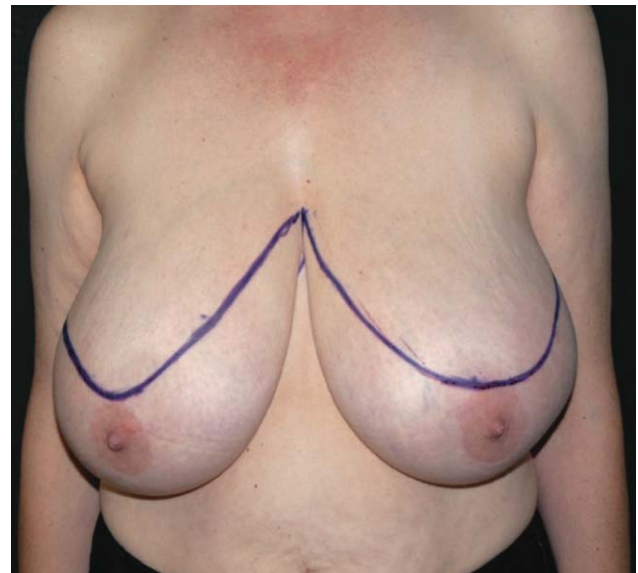


Fig. 1. Preoperative markings of a 43-year-old female patient with right breast stage 0 carcinoma.

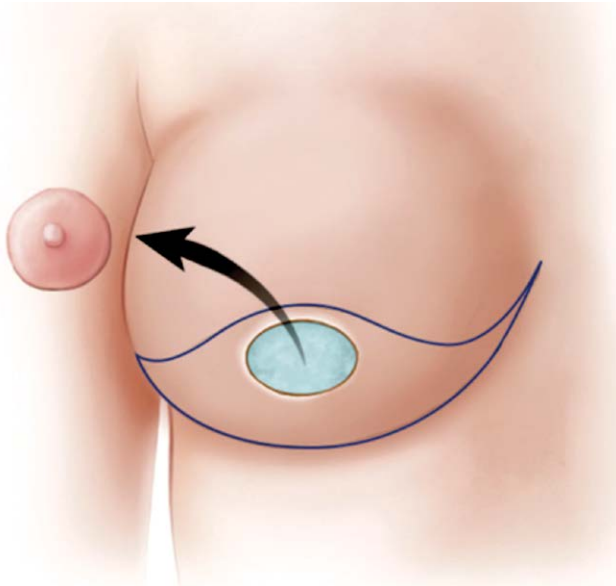


Fig. 2. Schematic of free nipple skin graft removal.

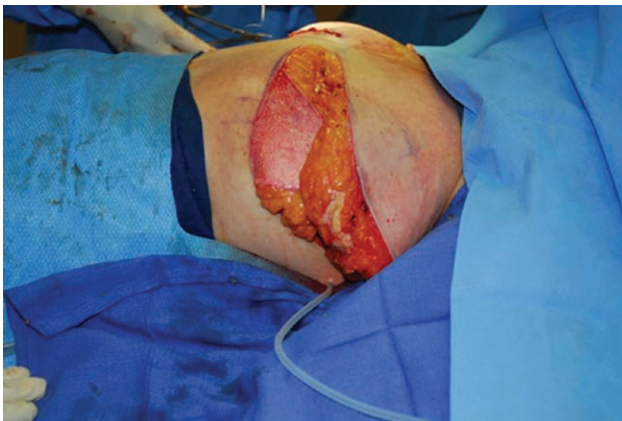

Fig. 3. Intraoperative lateral photograph of the de-epithelialized inferior flap.

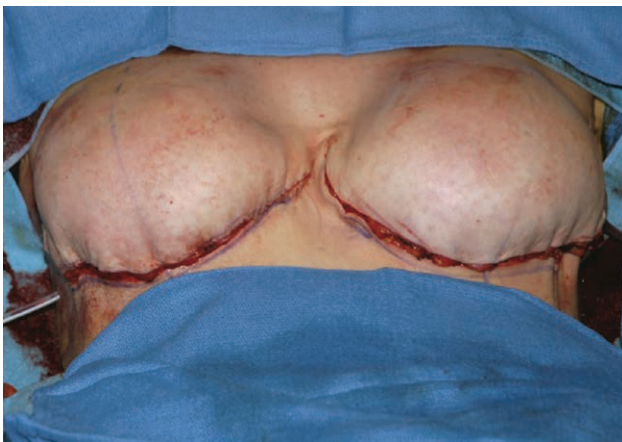


Fig. 4. Intraoperative photograph of the superior flap sutured over the de-epithelialized inferior flap.

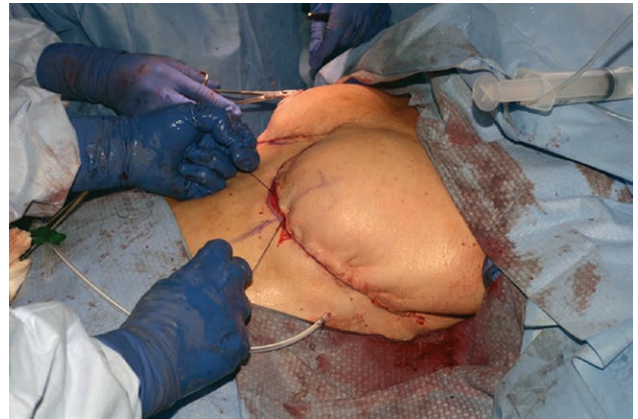

Fig. 5. Barbed sutures tightened to create inframammary fold and increase projection.

blue. The patients were then placed back supine, and these were infiltrated with dilute xylocaine with epinephrine. The skin was removed by de-epithelialization (Fig. 6). Jackson-Pratt drains were placed in each breast operated on. The banked NACs were then sutured into position using 4-0 interrupted silk sutures (Fig. 7). These were then tied over a bolster dressing (Fig. 8). Dressings were applied and the patients were taken to the recovery room in stable condition. The bolster dressings were removed approximately 1 week following the procedure.

RESULTS

Patient Characteristics

A total of 55 patients presented for breast reduction surgery from June of 1999 to March of 2021 and

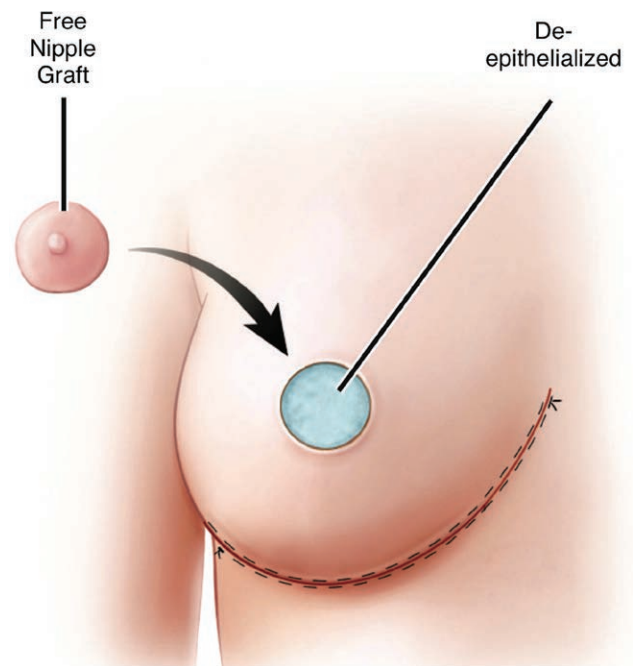


Fig. 6. Schematic of the free nipple graft placed over the de-epithelialized area on the superficial flap.

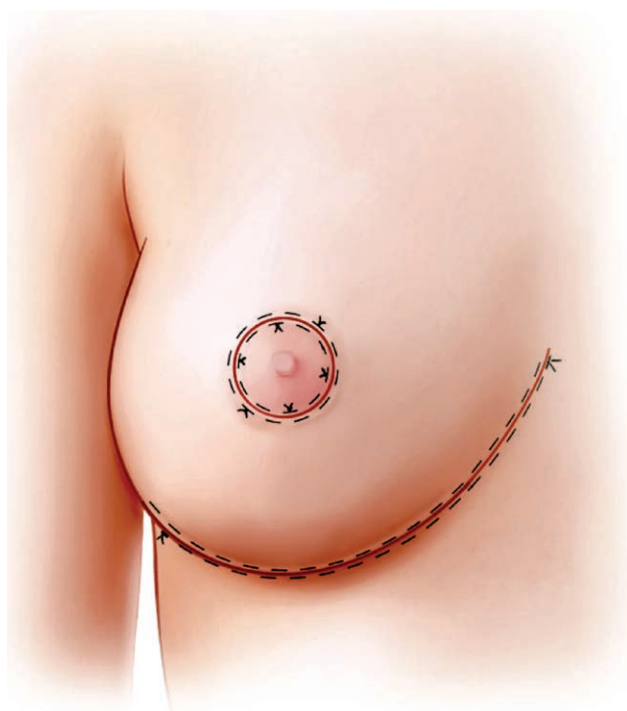

Fig. 7. Schematic showing the final result.

underwent a breast reduction using a free nipple graft with no vertical incision. After accounting for insufficient follow-up leading to incomplete documentation, a total of 46 cases (80 breasts) are described. Our postoperative follow-up time ranged from 3 to 209 months, with a median of 13.5 and a mean of 29.13, following reduction mammoplasty. The mean age was 60.3 and the median 61.5 at the time of surgery. The mean body mass index was 30.57 and the median 29.97 before the surgery. All patients presented with ptosis and 24 patients (52.17%) had a breast cancer diagnosis. No breast implants were used in any of the patients. Other relevant results and demographic data were shown in [Table 1](#).

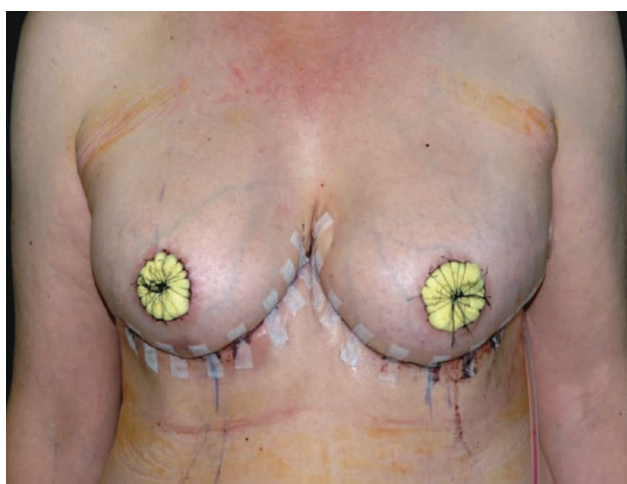


Fig. 8. Bolster dressing applied to the free nipple graft after suturing into position.

Table 1. Patient Demographics: Overall

Characteristic	Overall (%)
No. patients	46
Median age (y)	61.5
Mean age ± SD (y)	60.3±11.87
Median body mass index (kg/m ²)	29.97
Mean body mass index ± SD (kg/m ²)	30.57±6.27
<18.5	0
18.5–24.9	7 (15.22)
25.0–29.9	13 (28.26)
30.0–39.9	16 (34.78)
40+	4 (8.7)
Unknown	6 (13.04)
Other comorbidities	24 (52.17)
Breast cancer	24 (52.17)
Allergies	16 (34.78)
Smoking history	
Current	3 (6.52)
Former	8 (17.39)
On antiplatelets	6 (13.04)
On steroids	3 (6.52)
Previous breast surgery	14 (30.43)
Average tissue removal (g)	
Right breast	1146.81
Left breast	1139.09
Left breast	1155.14
Laterality of surgery	
Unilateral	12 (26.09)
Bilateral	34 (73.91)
Median follow-up time (mo)	13.5
Mean follow-up time ± SD (mo)	29.13±42.4
0–19	29 (63.04)
20–39	8 (17.39)
40–59	3 (6.52)
60–79	2 (4.35)
80–99	0
100+	4 (8.7)
Complications	5 (10.87)
Capsular contracture	1 (2.17)
Chronic incisional ulcer	1 (2.17)
Necrotic mastectomy flap	1 (2.17)
Revisional surgery	2 (4.35)

Our data were then divided into two groups: breast reconstruction (22 patients, 33 breasts) and breast reduction only (24 patients, 47 breasts). In terms of patient demographics, they were statistically different when it came to patient follow-up ($P < 0.05$), although the difference was insignificant when it came to age, body mass index, or other relevant factors ($P > 0.05$). Other pertinent results and demographic data are shown in [Table 2](#).

Outcomes

Postoperative images were taken at follow-up ([Fig. 9](#)). Other preoperative and postoperative images of the patients are shown in [Figures 10–12](#). A total of five patients had complications (10.87%). One patient, an active smoker, had a partial necrotic mastectomy flap (2.17%), one patient presented with chronic ulcers overlying the incision (2.17%), one patient had capsular contracture (2.17%), and two patients needed a revisional surgery (4.35%). We did not note any complications of areolar exudate, chronic postoperative pain, infection, hematomas, seromas, breakdown of the incisions, full nipple necrosis, or nipple loss.

There was no NAC surface area or diameter loss. However, there was some loss of nipple projection, particularly when an excessive amount of nipple tissue was retained. Additionally, there was one Black patient who

Table 2. Patient Demographics: Reconstruction versus Reduction Only

Characteristic	Breast Reconstruction (%)	Breast Reduction (%)
No. patients	22	24
Median age (y)	64	60.5
Mean age ± SD (y)	62.14±9.54	58.63±13.65
Median body mass index (kg/m ²)	28.3	32.9
Mean body mass index ± SD (kg/m ²)	28.9±6.91	32.4±5.03
<18.5	0	0
18.5–24.9	6 (27.27)	1 (4.17)
25.0–29.9	7 (31.82)	6 (25)
30.0–39.9	5 (22.73)	11 (45.83)
40+	3 (13.64)	1 (4.17)
Unknown	1 (4.55)	5 (20.83)
Other comorbidities	13 (59.09)	11 (45.83)
Breast cancer	22 (100)	2 (8.33)
Allergies	6 (27.27)	10 (41.67)
Smoking history		
Current	3 (13.64)	0
Former	3 (13.64)	5 (20.83)
On antiplatelets	4 (18.18)	2 (8.33)
On steroids	3 (13.64)	0
Prior breast surgery	9 (40.91)	5 (20.83)
Average tissue removal, g		
Right breast	875.25	1267.5
Left breast	839.11	1289.08
Total	921.71	1245.92
Laterality of surgery		
Unilateral	11 (50)	1 (4.17)
Bilateral	11 (50)	23 (95.83)
Median follow-up time (mo)	15	12.5
Mean follow-up time ± SD (mo)	42.82±56.63	16.58±15.65
0–19	13 (59.09)	16 (66.67)
20–39	2 (9.09)	6 (25)
40–59	2 (9.09)	1 (4.17)
60–79	1 (4.55)	1 (4.17)
80–99	0	0
100+	4 (18.18)	0
Complications	4 (18.18)	1 (4.17)
Capsular contracture	1 (4.55)	0
Chronic incisional ulcer	1 (4.55)	0
Necrotic mastectomy flap	1 (4.55)	0
Revisional surgery	1 (4.55)	1 (4.17)

lost areolar pigmentation. All patients were pleased with their results and healing outcomes according to clinical notes from all postoperative appointments.

DISCUSSION

Elimination of the vertical scar has been described previously with maintenance of an inferior pedicle by Passot in 1925 and by Lalonde in 2003.^{12,13} However, in certain cases, maintaining the nipple on a pedicle results in increased complexity of the procedure and may not be necessary, particularly in very ptotic elderly patients. Currently, the common approaches to reduction mammoplasties involve the use of the Wise pattern, leading to an anchor incision, vertical incision, circumareolar, or the free nipple graft with the use of the vertical incision.¹⁴ Our literature review revealed that there have been very few mentions of using a free nipple graft without the vertical incision for breast reductions. One of them is the Robertson technique described in the 1960s, which resulted in a bell-shaped transverse scar passing through the mid horizontal axis of the breast.^{15,16} Another is a study of 18 patients by Manstein et al,¹⁷ where they describe a free nipple graft breast reduction without a vertical incision using a trapezoid-shaped dermoglandular flap to

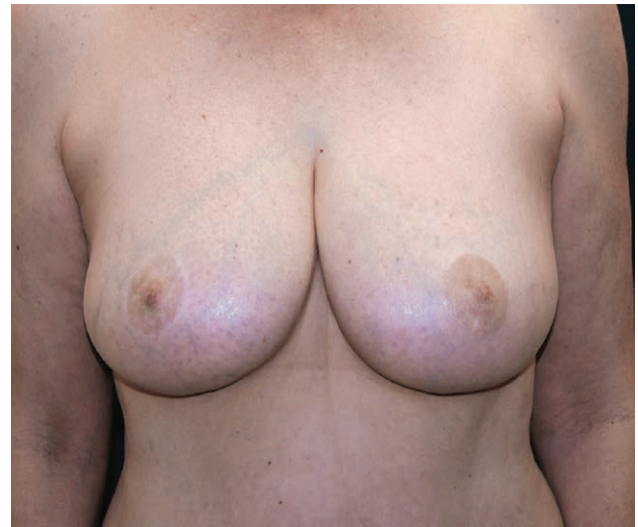

Fig. 9. Postoperative photograph of a 43-year-old female patient who presented with right breast stage 0 carcinoma for bilateral breast reduction at 15 months.

create a breast mound. They found that this technique led to every nipple graft having some degree of crusting or depigmentation, but no other major complications. A modification of the Robertson technique describes a procedure for breast reductions termed the “Boston modification,” where the authors use no vertical incision, but an inferior pedicle nipple areolar complex to improve the aesthetic appearance and eliminate the need for a free nipple graft.¹⁸ Additionally, Echo et al introduced a breast reduction technique utilizing a dermal suspension sling without the use of a vertical incision. In this study, the nipple was maintained on a pedicle, which preserved NAC sensation.¹⁹ However, removing the nipple allows for further elevation of the pedicle to place it in a more aesthetic position and to enhance breast projection.

The technique of a free nipple graft with only an inframammary incision offers promising postoperative results. The lack of a vertical incision reduces scarring and reduces the risk of dehiscence. The use of the free nipple graft allows women with macromastia to undergo a reduction mammoplasty preserving their NAC as a graft. It also allows for a wider range of parenchyma reduction with a more aesthetic breast shape because the inferior pedicle of the breast can be elevated into the upper pole, which enhances the breast shape and breast fullness. A free nipple graft can also be used to reduce the risk for breast cancer in patients having a symmetrizing procedure following a mastectomy because it allows for a substantial reduction of the subareolar breast tissue. The parenchyma reduction also allows for easier examination and screening procedures to detect breast cancer in the future. Additionally, it is possible to perform a mastectomy and contralateral reduction utilizing the same type of incision for aesthetic purposes.^{20,21} The principal investigator has found that this technique can be performed more rapidly with less blood loss, and patients are usually discharged on the same day, even if an excess of 1000 grams of tissue has been removed.

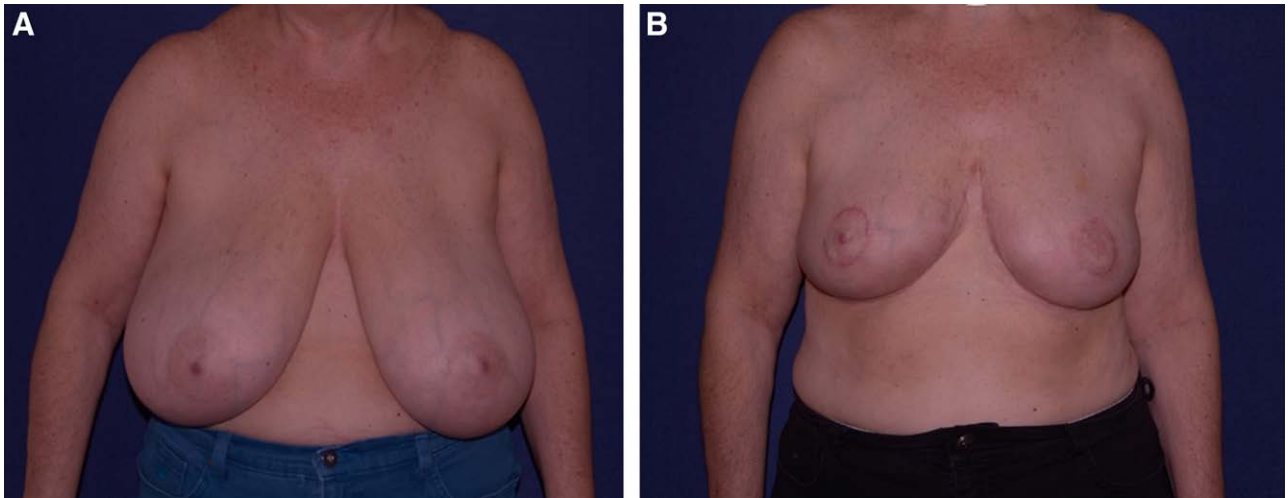


Fig. 10. Images of preoperative and postoperative results utilizing a free nipple graft without a vertical incision. A, Preoperative and B, 4-months postoperative photographs of a 57-year-old female patient who presented for breast reduction surgery.

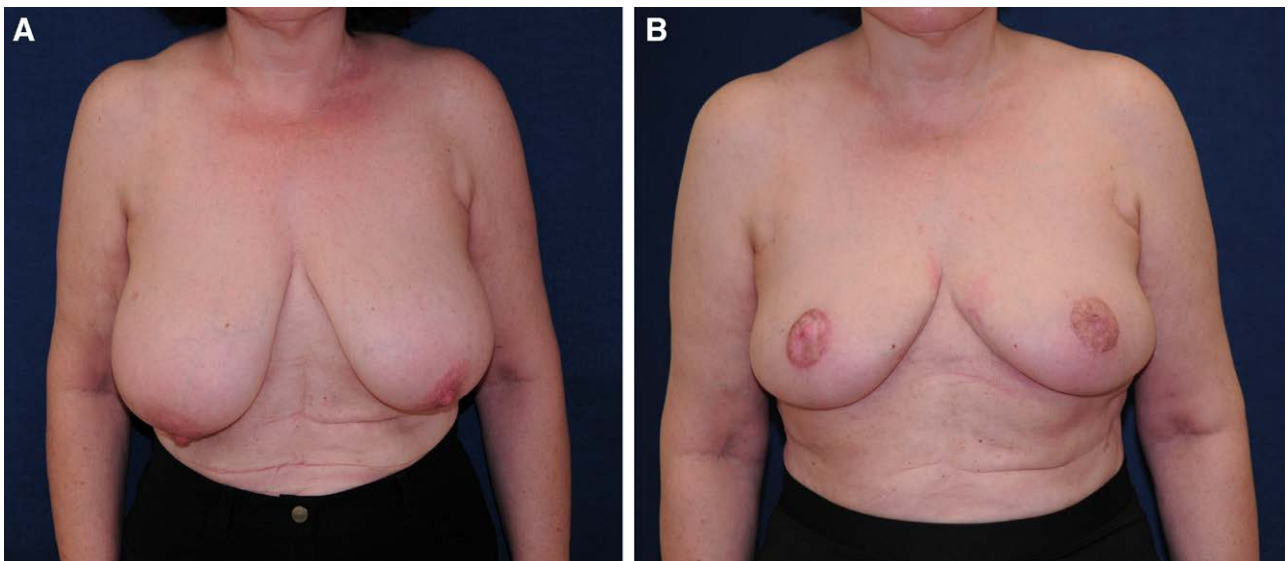


Fig. 11. Images of preoperative and postoperative results utilizing a free nipple graft without a vertical incision. A, Preoperative and B, 6-months postoperative photographs of a 61-year-old female patient who presented for breast reduction surgery.

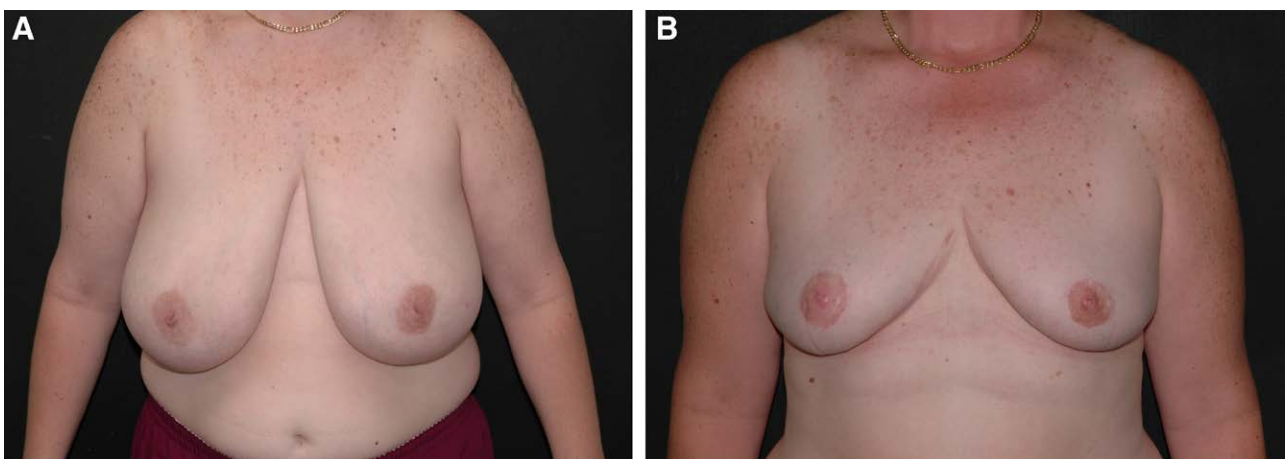


Fig. 12. Images of preoperative and postoperative results utilizing a free nipple graft without a vertical incision. A, Preoperative and B, 20-months postoperative photographs of a 42-year-old female patient who presented for breast reduction surgery.

The disadvantages of performing a free nipple graft include a loss of nipple sensation, the inability to breast-feed, and the fact that the nipple graft utilizes imbibition for vascular supply initially. Although nipple sensation was not directly measured in this study, patients reported decreased nipple sensation postoperatively. However, all patients regained tactile sensitivity under the graft over time. Furthermore, the lack of direct vascular supply to the graft can cause postoperative superficial nipple necrosis. This condition is temporary and treated conservatively. It typically resolves shortly after shedding the necrotic eschar. Further, there is the concern of postoperative NAC hypopigmentation, particularly in patients with darker skin. This can be minimized by using a very thick graft, which can be accomplished by removing subareolar tissue. Finally, tattooing can also be used for pigment replacement.²²

CONCLUSIONS

The free nipple graft technique with an inframammary incision is an option for reduction mammoplasties that merits further investigation. It offers the ability to reduce the breast size and avoid the use of the vertical incision. This will limit scarring to optimize the aesthetic outcome, and will also avoid complications from wound dehiscence at the T-junction. This technique can also be used to obtain good projection by retaining the inferior flap and suturing it into the upper pole without concern for adequate perfusion of the nipple areolar complex. As breast reductions become more common, additional research regarding surgical techniques and outcomes are warranted.

Oscar Adrian Vazquez, MD, MS

777 Glades Rd, BC-71

Boca Raton, FL 33431

E-mail: ovazquez2017@health.fau.edu

REFERENCES

- Gonzalez F, Walton RL, Shafer B, et al. Reduction mammoplasty improves symptoms of macromastia. *Plast Reconstr Surg*. 1993;91:1270–1276.
- Lo AY, Yu RP, Raghuram A, et al. Patient characteristics associated with free nipple graft reduction mammoplasty. *Cureus*. 2020;12:e9063.
- DeGeorge BR Jr, Colen DL, Mericli AF, et al. Reduction mammoplasty operative techniques for improved outcomes in the treatment of gigantomastia. *Eplasty*. 2013;13:e54.
- Van Thienen CE. Areolar vertical approach (AVA) mammoplasty: Lejour's technique evolution. *Clin Plast Surg*. 2002;29:365–377.
- Hall-Findlay EJ, Shestak KC. Breast reduction. *Plast Reconstr Surg*. 2015;136:531e–544e.
- Nahabedian MY, Mofid MM. Viability and sensation of the nipple-areolar complex after reduction mammoplasty. *Ann Plast Surg*. 2002;49:24–31.
- Brown RH, Siy R, Khan K, et al. The superomedial pedicle wise-pattern breast reduction: reproducible, reliable, and resilient. *Semin Plast Surg*. 2015;29:94–101.
- Vazquez OA, Becker H. Healing of bilateral nipple areolar complex necrosis by secondary intention. *Cureus*. 2020;12:e9025.
- Egozi D, Allwies TM, Fishel R, et al. Free nipple grafting and nipple sharing in autologous breast reconstruction after mastectomy. *Plast Reconstr Surg Glob Open*. 2020;8:e3138.
- Daane SP, Rockwell WB. Breast reduction techniques and outcomes: a meta-analysis. *Aesthet Surg J*. 1999;19:293–303.
- Colen SR. Breast reduction with use of the free nipple graft technique. *Aesthet Surg J*. 2001;21:261–271.
- Passot R. La correction esthetique du prolapsus mammaire par le procede de la transposition du mamelon. *Presse Med*. 1925;33:317–318.
- Lalonde DH, Lalonde J, French R. The no vertical scar breast reduction: a minor variation that allows to remove vertical scar portion of the inferior pedicle wise pattern T scar. *Aesthetic Plast Surg*. 2003;27:335–344.
- Purohit S. Reduction mammoplasty. *Indian J Plast Surg*. 2008;41 (suppl):S64–S79.
- Robertson DC. Reduction mammoplasty using a large inferior flap. In: *Transactions of Third International Congress of Plastic Surgery*. Amsterdam: Excerpta Medical Foundation; 1964:81.
- Robertson DC. The technique of inferior flap mammoplasty. *Plast Reconstr Surg*. 1967;40:372–377.
- Manstein ME, Manstein CH, Manstein G. Obtaining projection in the amputation free nipple/areolar graft breast reduction without a vertical scar: using breast parenchyma to create a new mound. *Ann Plast Surg*. 1997;38:421–424.
- Movassaghi K, Liao EC, Ting V, et al. Eliminating the vertical scar in breast reduction—Boston modification of the Robertson technique. *Aesthet Surg J*. 2006;26:687–696.
- Echo A, Guerra G, Wolfswinkel EM, et al. No-vertical-scar inferior pedicle breast reduction using the dermal suspension sling. *Eur J Plast Surg*. 2013;37:21–28.
- Ghidei L, Bansil HA, Stuckey A, et al. Nipple-sparing mastectomy and ptosis. *Plast Reconstr Surg Glob Open*. 2020;8:e2623.
- Kim EK, Cho JM, Lee JW. Skin-sparing mastectomy and immediate nipple graft for large, ptotic breast. *J Breast Cancer*. 2019;22:641–646.
- Becker H. The use of intradermal tattoo to enhance the final result of nipple-areola reconstruction. *Plast Reconstr Surg*. 1986;77:673–676.