

Vertical Mastectomy Incision With One Stage Immediate Pre-pectoral Reconstruction

HILTON BECKER, M.D., F.A.C.S., F.R.C.S



American Society
of Breast Disease
www.asbd.org

18th SIS World Congress on
Breast Healthcare

October 16-19, 2014, Orlando, Florida



SENOLOGIC
INTERNATIONAL
SOCIETY
www.sisbreast.org

Vertical Mastectomy Incision With One Stage Immediate Pre-pectoral Reconstruction

The results of breast reconstruction are largely related to the quality of the tissue that remains after mastectomy. With the evolution of less radical mastectomies, the quality of the residual tissue has improved, largely contributing to better breast reconstructive results.

The most common method of breast reconstruction involves the sub-muscular placement of a tissue expander, and subsequent replacement of the expander with a silicone gel implant.

Expanders have been traditionally placed in a sub-muscular pocket due to concerns with thin and poorly vascularized skin flaps that remain after mastectomy. As the inferior muscle is thinner and unpredictable, horizontal incision has been preferred because it allows the thicker upper muscle to protect the expander.

Although excellent results have been obtained using this method, scarring, discomfort and animation deformities are often problematic complications.

As mastectomies have evolved from radical to modified radical, including skin and now nipple sparing, the quality of the remaining skin flaps has improved. With less concern for compromised vascularity, it is now possible to place an expander above the muscle, allowing for total freedom of incision placement.

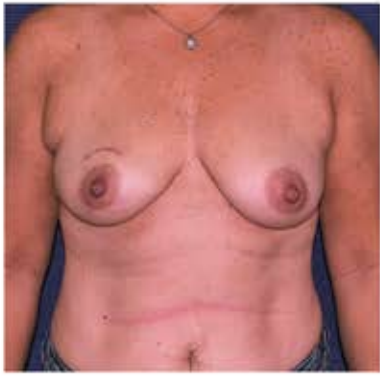Advantages to a vertical incision:

From the surgical excision perspective, a vertical incision improves access for the mastectomy with comparable visualization while decreasing risk of vascular damage to the skin flaps.

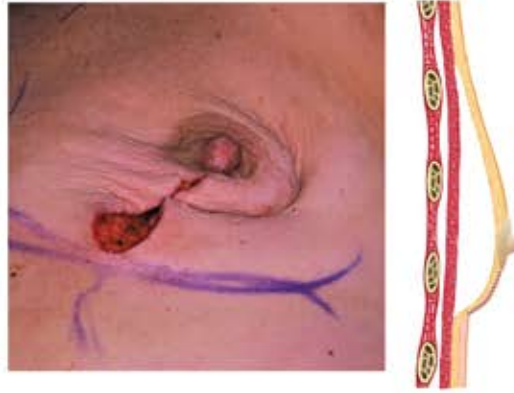From an oncological perspective, the supra-muscular technique is advantageous because no additional tissue planes are opened, decreasing the area for potential surgical seeding of cancerous cells.

From a reconstructive perspective, this technique supports:

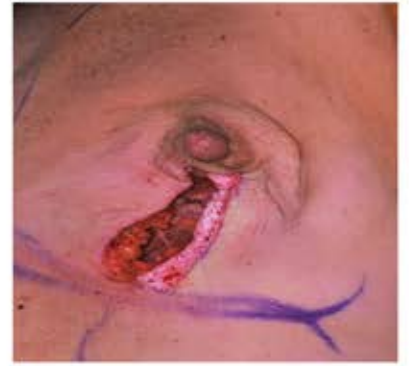1. Improved cosmetic result: the scar resembles that of a breast lift
2. Less interference with blood supply to flaps: the incision runs parallel to the direction of blood flow, running in the watershed of the lateral and medial blood supply to the breast
3. Improved initial shape: revision of the scar does not cause distortion of breast shape
4. Improved nipple position: the nipple does not tend to drift laterally or superiorly
5. Applicability to a variety of breasts: the technique is applicable to small breasts and to large ptotic breasts (particularly where reduction and/or elevation is necessary)
6. A more natural feel: pre-pectoral placement approximates the natural position of the removed breast tissue
7. Less muscular trauma: resulting in less pain and more rapid recovery
8. Less pressure on flaps: the use of an adjustable flat expander with a remote port, placed under-filled, causes no increased pressure to the flaps during the immediate recovery phase. The expander can later be adjusted to the patient's preference
9. A thicker natural flap: the vertical incision allows for de-epithelialization of a portion of the lateral flap, which can be tucked beneath the medial flap to offer added protection and support to the implant. Similarly, further tightening and elevation can be performed post-operatively without additional scarring
10. Post operative enhancements: thin skin flaps or depressed areas can be further enhanced by the addition of acellular dermis, or through fat injections



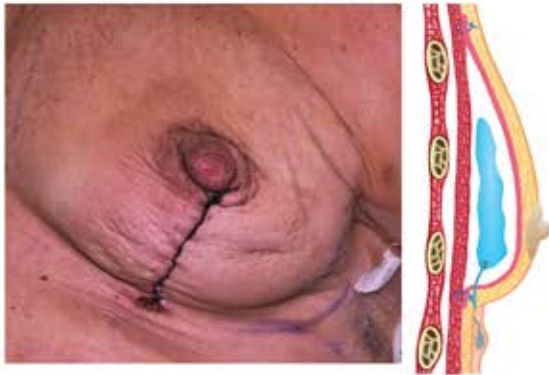
1. Patient prior to surgery



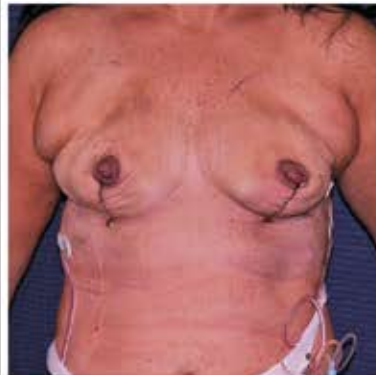2. Following mastectomy via vertical incision



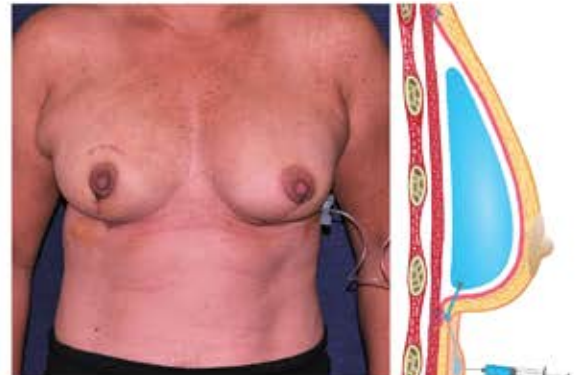3. Lateral flap de-epithelialized



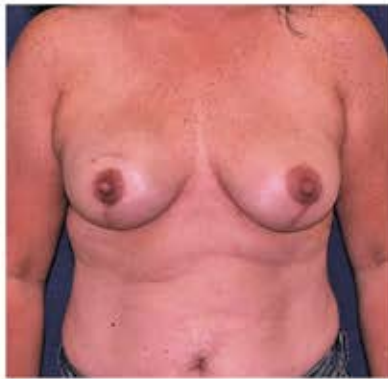4. Following pre-pectoral placement of adjustable saline implant with two layered skin closure



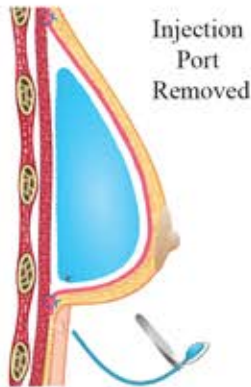5. Post operative result with implants underfilled.



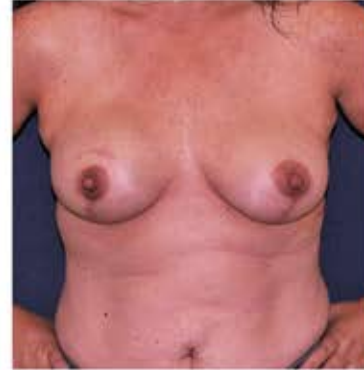6. Saline added to implants



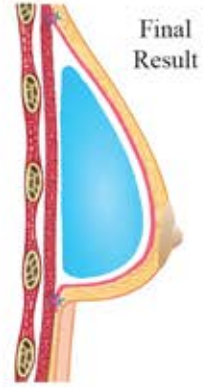7. Final result



Injection Port Removed

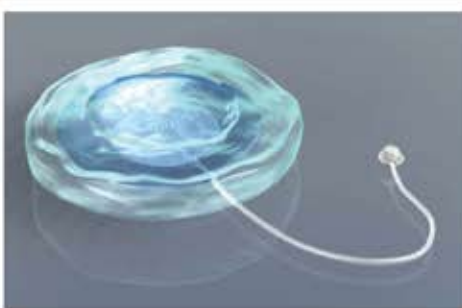


8. No animation deformity on muscle contraction

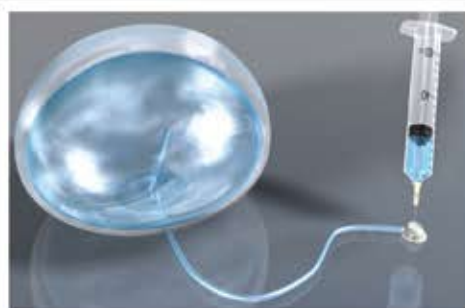

Final Result


The Adjustable Breast Implant



1. Implant empty, Injection port attached



2. Saline added via injection port



3. Injection port removed

HILTON BECKER, M.D. CLINIC OF PLASTIC SURGERY

Sandler Medical Plaza ♦ 670 Glades Road, Suite # 220, Boca Raton, FL 33431 ♦ (561) 394-6656

Affiliate Associate Professor of Clinical Biomedical Science | Florida Atlantic University College of Medicine

Voluntary Faculty | Cleveland Clinic Florida Department of Plastic Surgery

www.beckermd.com | www.adjustablegelimplant.com