

Augmentation Mastopexy Using Adjustable Implants With External Injection Domes

For augmentation mastopexy, the authors use adjustable implants that are deflated at the end of the procedure and then inflated to the desired size 5 to 10 days postoperatively using external injection domes. Reported advantages, based on 175 cases, include increased perioperative safety for the nipple areolar complex, the ability to adjust for size and symmetry postoperatively with patient input, and better scar healing with less widening. (*Aesthetic Surg J* 2006;26:736-740.)

Augmentation mastopexy is recognized as a difficult procedure with a high complication rate. Some surgeons advocate performing the operation in 2 stages) The mastopexy procedure tightens the skin and elevates the inframammary fold; the augmentation procedure does the opposite, expanding the skin and lowering the inframammary fold. If a fixed volume implant is used, a tight skin closure over a large implant may lead to scar stretching, wound breakdown, skin necrosis and even, on rare occasions, nipple areolar complex loss. Furthermore, the tight closure tends to elevate the implant (Figure 1).²

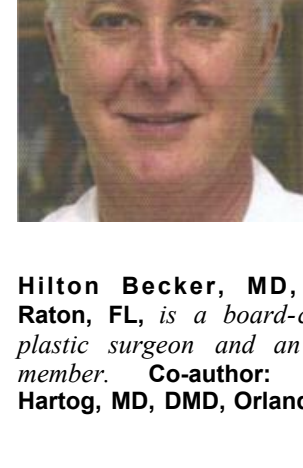
The adjustable implant allows for initial placement of the implant in an underfilled state and subsequent filling a few days after surgery, once viability of the skin flaps is assured. With this device, optimal size and symmetry can be achieved and postoperative pain is reduced.

The standard technique for using the adjustable implant is to place the injection dome in a subcutaneous pocket; the dome is removed several months later when surgeon and patient are satisfied with the size and shape of the breasts (Figure 2).³⁻⁵ For patients who do not wish to undergo injection dome removal, it is possible to externalize the injection dome for several days.⁶

The use of adjustable implants for augmentation mastopexy with buried injection domes, as well as augmentation with externalization, have been previously reported. Here, we present the use of an external injection dome for augmentation mastopexy.

Technique

Preoperatively, determine the implant size by measuring the base diameter on the chest and then having the patient try on the selected implant in a bra. Any of the standard mastopexy incisions may be used. Most commonly, we use the subareolar version of the circumareolar technique or the vertical mastopexy. If the subglanular pocket is selected, we use the 50/50 gel/



Hilton Becker, MD, Boca Raton, FL, is a board-certified plastic surgeon and an ASAPS member. Co-author: Jeffrey Hartog, MD, DMD, Orlando, FL.

saline implant. For a submuscular pocket, either the adjustable saline or the 50/50 gel/saline implant can be used (Figure 3).

The vertical mastopexy procedure can be also performed using external injection domes (Figure 4). Use a temporary sizer implant initially to reconfirm the size.

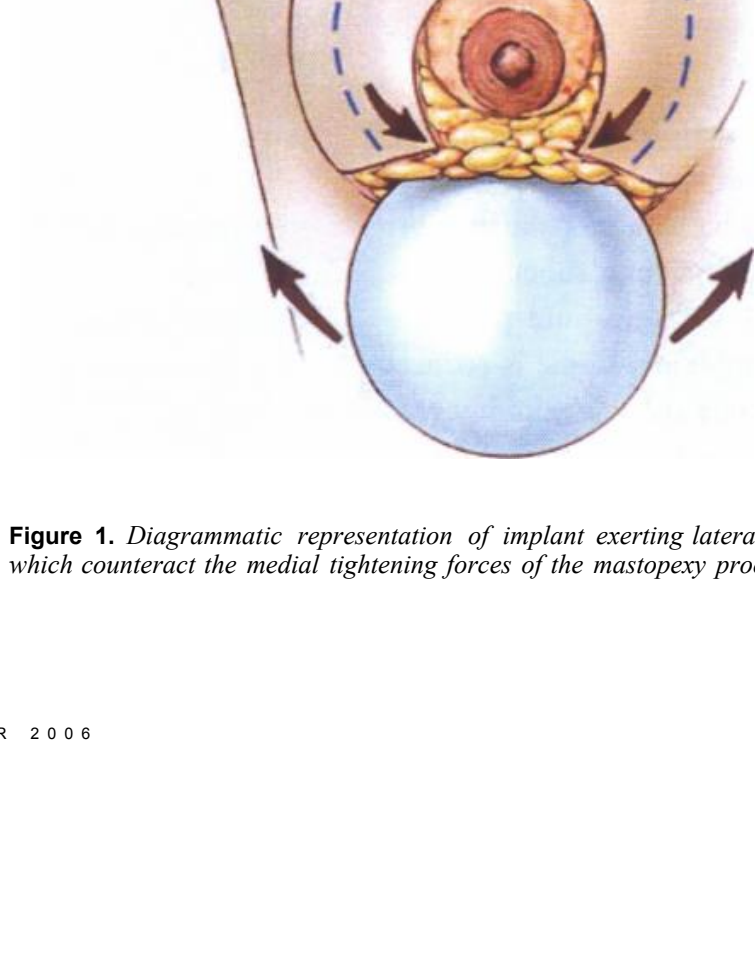


Figure 1. Diagrammatic representation of implant exerting lateral forces, which counteract the medial tightening forces of the mastopexy procedure.

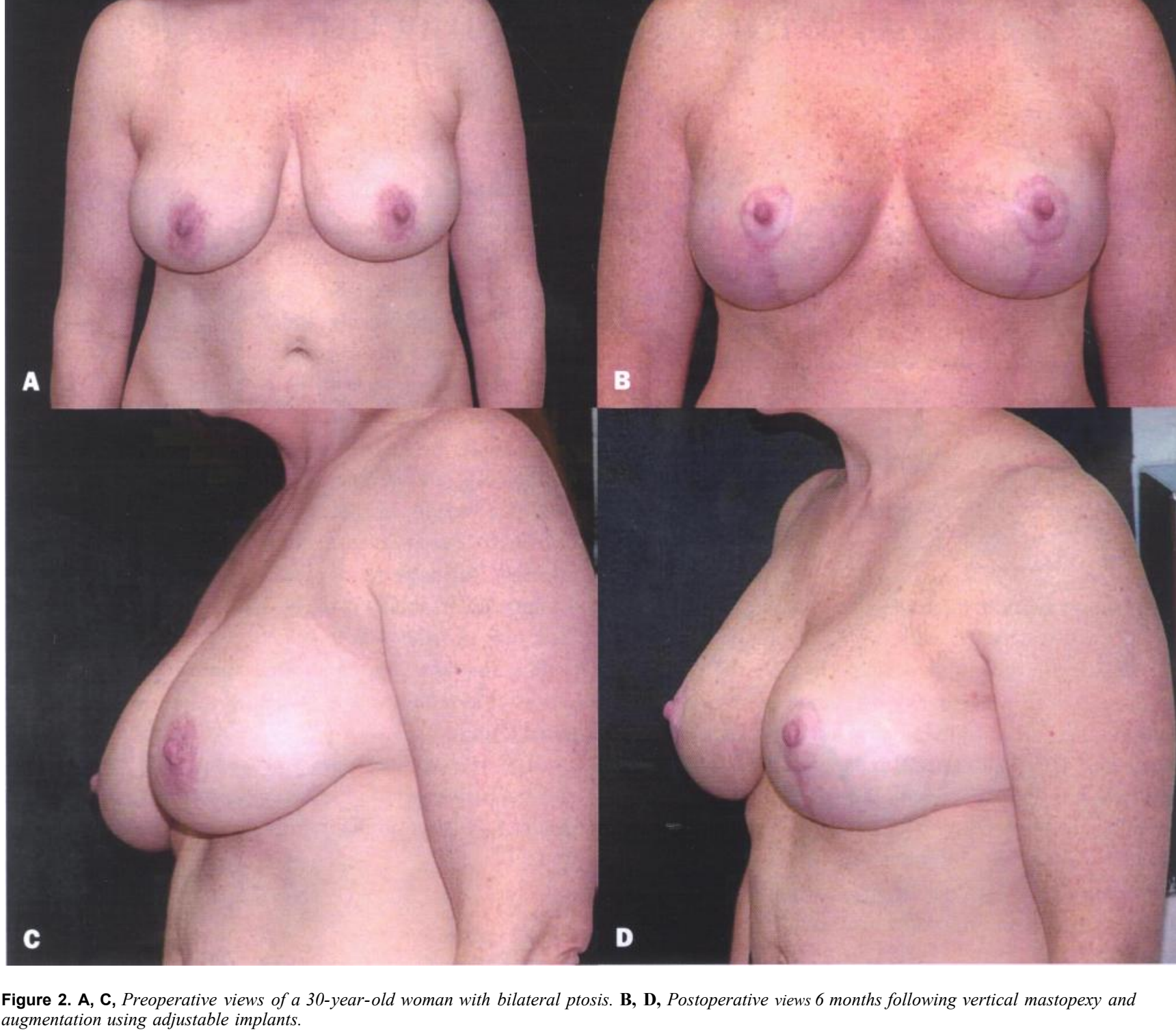


Figure 2. A, C, Preoperative views of a 30-year-old woman with bilateral ptosis. B, D, Postoperative views 6 months following vertical mastopexy and augmentation using adjustable implants.

Then perform the mastopexy. Replace the temporary sizer with the definitive adjustable implant. Attach the filling tube to a trochar and bring it out through the skin through a long subcutaneous tunnel. Fill the implant to the desired size and perform skin closure. At this stage the implant volume is reduced about 25% or to a point at which there is minimal tension on the incision.

Place a Tegaderm dressing (3M, St. Paul, MN) over the injection dome. Five to 10 days later, when the patient is seen postoperatively, execute the final implant filling, and remove the dome and filling tube.

Discussion

The adjustable implant procedure has many advantages for mastopexy augmentation. The ability to under-fill the implant at surgery allows for initial tension-free wound healing, thus reducing the risk of complications. The final implant volume can be adjusted to optimally fill the newly created breast envelope.

By avoiding excessive tension on the skin during the healing period there is less chance of wound breakdown. Scars heal more rapidly and ultimately remain finer. The ability to increase the volume after surgery not only

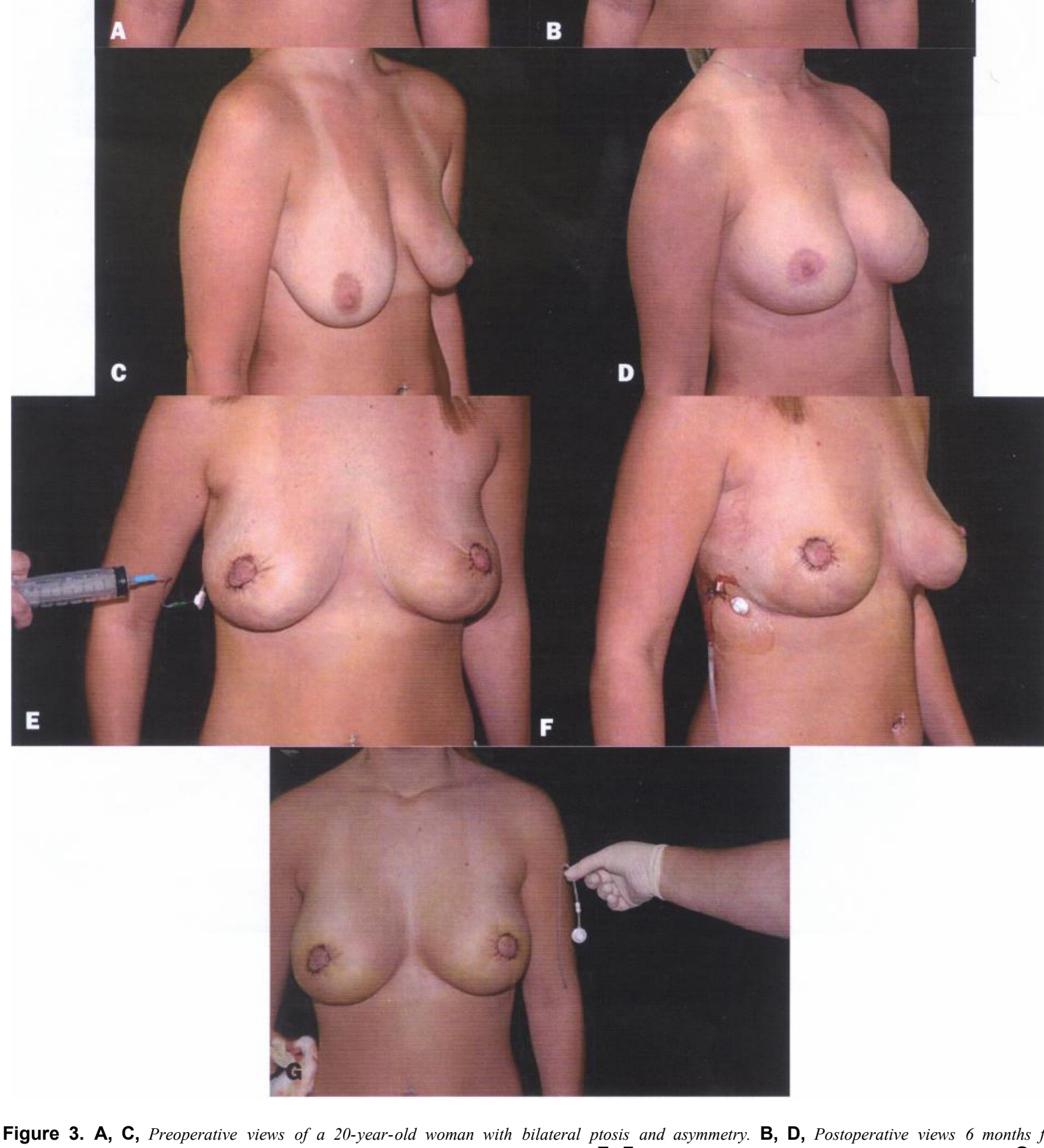


Figure 3. A, C, Preoperative views of a 20-year-old woman with bilateral ptosis and asymmetry. B, D, Postoperative views 6 months following augmentation mastopexy using adjustable implants with external injection domes. E, F, Implant further filled via external injection dome. G, Injection dome removed 1 week after surgery.

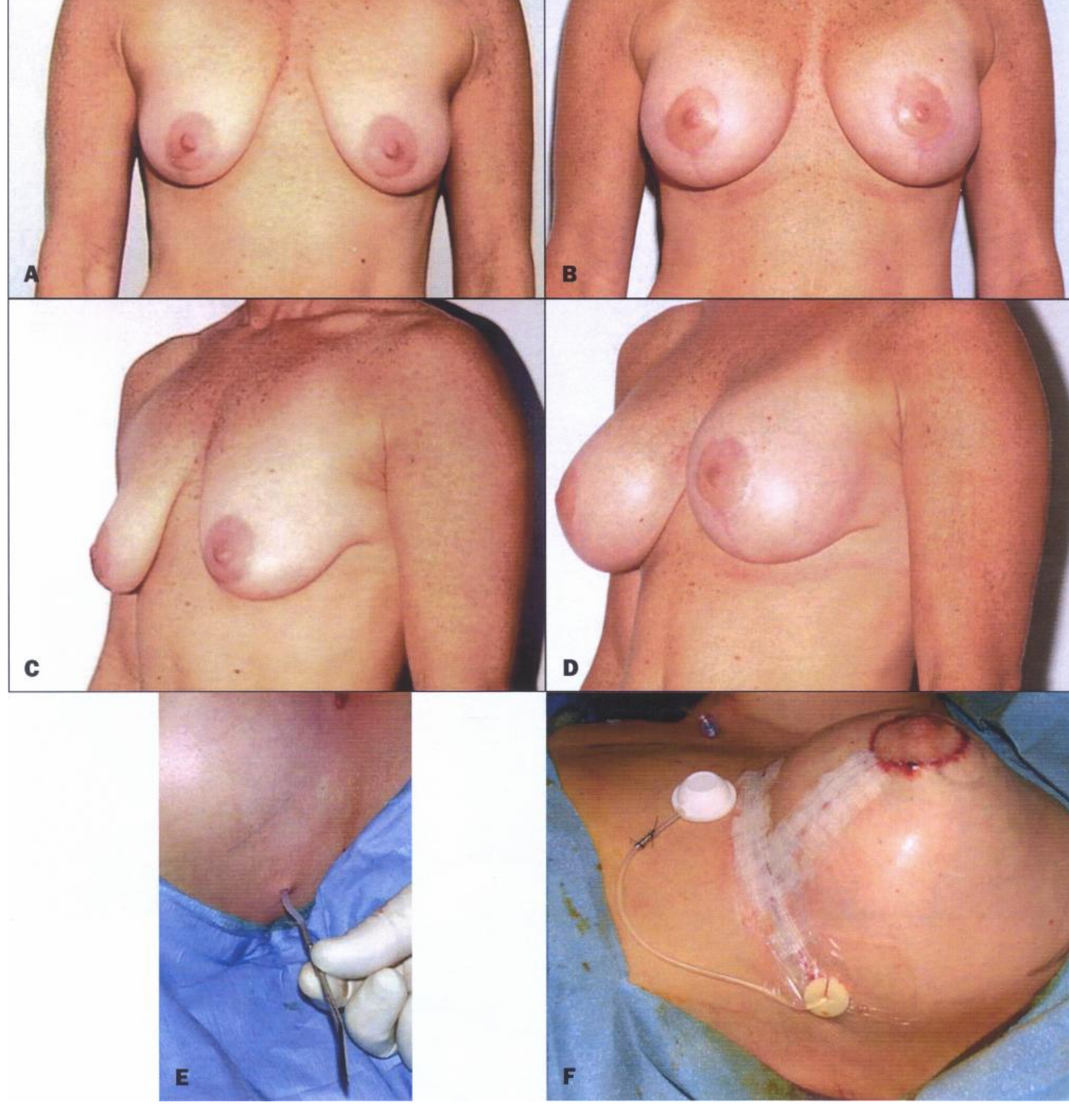


Figure 4. A, C, Preoperative views of a 47-year-old woman with bilateral ptosis. B, D, Postoperative views 7 months following vertical mastopexy and augmentation using Spectrum implants. E, The trochar is used to tunnel the fill tube subcutaneously. F, Tension free closure and external injection dome.

CLINICAL INSIGHTS

allows the patient to have input into her final size, but by increasing size, projection is increased and more lift is attained. Further, better symmetry can be achieved, especially if the breasts were uneven before surgery.⁷⁻⁹

The concept of external filling domes was first described by Jackson,^{10,11} and the domes have been used for breast augmentation with no reported incidence of retrograde infection. The external filling dome has been acceptable to those patients who wish to take advantage of postoperative adjustability without having to undergo a second minor procedure to remove the domes. ■

References

- Fisher J, Maxwell GP. Selection of technique for augmentation mammoplasty. In: Noone RB, editor. *Plastic and Reconstructive Surgery of the Breast*. Hamilton, Ontario: BC Decker, 1991.
- Becker H. Adjustable breast implants provide postoperative versatility. *Aesthetic Surg J* 2000;20:332-334.
- Becker H. Expansion augmentation. *Clin Plast Surg* 1988;15:587-593.
- Becker H. Breast augmentation using the expander mammary prosthesis. *Plast Reconstr Surg* 1987;79:192-199.
- Becker H, Persoff MM. Expansion augmentation of the breast. *Plast Reconstr Surg* 1993;91:393.
- Becker H. Breast augmentation using the spectrum implant with exteriorized injection domes. *Plast Reconstr Surg* 2004;114:1617-1620.
- Becker H. The correction of breast ptosis with the expander mammary prosthesis. *Ann Plast Surg* 1990;24:489-497.
- Becker H. The dermal overlap subareolar mastopexy: a preliminary report. *Aesthetic Surg J* 2001;21:423-427.
- Persoff M. Mastopexy with expansion-augmentation. *Aesthetic Surg J* 2003;23:34-39.
- Jackson I, Sharpe D, Polly J, et al. Use of external reservoirs in tissue expansion. *Plast Reconstr Surg* 1987;80:266-273.
- Jackson I. Immediate breast reconstruction with prolonged over expansion using the Becker permanent expander prosthesis. *Eur J Plast Surg* 1992;15:79.

Reprint requests: Hilton Becker, MD, FACS, 5458 Town Center Road, Suite 101, Boca Raton, FL 33486.

Copyright © 2006 by The American Society for Aesthetic Plastic Surgery, Inc.

1090-820X / \$32.00
doi:10.1016/j.asj.2006.10.014